142 Surgical Anatomy of the Head and Neck

Franklin P. Flowers, Charya B. Goldsmith and Matthew Steadmon

Chapter Contents

Topographic Anatomy of the Head and Neck 2464
Skin Tension Lines 2465
Cosmetic Subunits. 2467
Free Margins 2467
The Superficial Musculoaponeurotic System 2469
Muscles of Facial Expression 2471
Vascular Anatomy 2473
The Facial Nerve 2474
Sensory Innervation of the Head and Neck 2476
Lymphatic Drainage of the Head and Neck 2477

Key features

- The muscles of facial expression all arise from the second branchial arch, are concentrated in the central facial region, and receive their motor innervation from the facial nerve (cranial nerve VII)
- The superficial musculoaponeurotic system (SMAS) is a fibromuscular layer that ensheathes and connects the facial muscles and plays an intricate role in coordinating facial expressions
- The SMAS can be utilized as a guide to dissection, tissue mobilization, and closure, thereby minimizing trauma to neurovascular tissues
- The three branches of the trigeminal nerve (cranial nerve V) provide sensory innervation to the face, while various branches of the cervical plexus provide sensory innervation to the neck, parts of the ear, and posterior scalp
- Familiarity with the muscular and neurovascular structures of the head and neck region allows the surgeon to properly approach the "danger zones", e.g. Erb's point in the neck, the temporal nerve as it crosses the zygomatic arch, and the marginal mandibular nerve at the jawline just anterior to the masseter muscle
- The rich and anastomosing vascular supply of the face and scalp, derived from both the external and internal carotid arteries, explains the excellent healing potential and viability of local flaps and grafts in this region
- Cosmetic subunits and the junction lines separating them should be considered when planning excisions, repairs, and cosmetic procedures of the head and neck

The dermatologic surgeon must have a comprehensive knowledge of regional anatomy in order to obtain acceptable operative results. Proper tissue movement on the face and neck is essential for obtaining closures that are under minimal tension without cosmetic distortion or functional loss of vital structures. In addition to reducing postoperative morbidity, a fundamental appreciation for the macromechanics of the head and neck leads to preservation of tissue viability as well as sensory and motor innervation[1,2]. The fascial planes, vascular supply, innervation, and cosmetic subunits of the face must be considered when planning a surgical or cosmetic procedure. In order to accurately and thoroughly counsel patients regarding procedural risks and benefits, the surgeon must have a thorough appreciation of head and neck anatomy.

TOPOGRAPHIC ANATOMY OF THE HEAD AND NECK

It is possible to pinpoint underlying anatomic structures of the head and neck by observing surface anatomy. The bony structure of the face serves as a simple anatomic framework (Fig. 142.1). The supraorbital ridges are formed by the frontal bone and are more prominent in men. The supraorbital foramen transmits the supraorbital nerve (from the ophthalmic division of the trigeminal nerve) and its associated artery and vein. This foramen is palpable on the bony supraorbital ridge at the vertical midpupillary line. This line lies approximately one finger-breadth lateral to the lateral nasal root or 2.5 cm lateral of the midline on the face (Fig. 142.2). Other important foramina lie in this midpupillary line and transmit important neurovascular bundles. The infraorbital foramen is located 1 cm below the infraorbital rim in the midpupillary line. It transmits the infraorbital nerve (from the maxillary division of the trigeminal nerve) and its associated artery and vein. The mental foramen lies in the same vertical line in the midportion of the mandible. The mental neurovascular bundle emerges here as a terminal sensory branch of the mandibular division of the trigeminal nerve.

The anterior border of the temporalis muscle can be palpated in the temporal fossa above the zygomatic bone. The latter bone forms the malar eminence of the cheek. The buccal fat pad provides fullness to the cheek; elderly or cachectic patients often have very prominent zygomatic arches. These arches form the widest points on the face and serve as the point of attachment for several muscles of facial expression and for the masseter muscle. The masseter muscle spans the zygomatic arch and mandibular ramus, serving as a muscle of mastication innervated by a motor branch of the trigeminal nerve (see below). This muscle is easily palpated by clenching the jaw.

The parotid gland lies beneath the subcutaneous fat of the lateral cheek and is invested by parotid fascia. The superficial lobe of the parotid covers the posterior half of the masseter muscle and extends from the preauricular sulcus to the angle of the mandible. The deep lobe lies on the medial side of the ramus of the mandible and is connected to the superficial lobe by an isthmus. The superficial temporal artery and vein, as well as branches of the facial nerve (which provides motor innervation to the muscles of facial expression), course through the parotid gland in channels between glandular tissue[3]. The duct of the parotid gland (Stensen's duct) travels across the anterior surface of the masseter muscle (Fig. 142.3). After crossing the muscle surface, the duct penetrates deeper to pierce the buccinator muscle and eventually drains into the mouth at the level of the second upper molar. It can be palpated as a "cord" crossing a clenched masseter muscle. If the duct is transected, a chronic draining fistula will form, requiring corrective surgical intervention. Stensen's duct can be identified topographically by drawing a line between the tragus and the midportion of the cutaneous upper lip. The duct traverses the masseter muscle at the middle one-third of this line (see Fig. 142.3).

Several structures of importance can be located by observing the surface anatomy of the neck. The sternocleidomastoid muscle is comprised of two heads originating from the sternum and the medial one-third of the clavicle. It inserts onto the outer surface of the mastoid process and nuchal ridge, dividing the neck into anterior and posterior triangles. A dermatologic surgeon should be familiar with the anatomic structures that lie within each of these topographic triangles. Although the sternocleidomastoid muscle covers and protects most of the major anatomic structures in the neck, the external jugular vein traverses its surface with many cutaneous sensory nerves of the cervical plexus (Fig. 142.4). In addition, the posterior triangle of the neck contains trunks of the brachial and cervical plexus as well as the spinal accessory

Downloaded for Anonymous User (n/a) at Egyptian Knowledge Bank from ClinicalKey.com by Elsevier on March 10, 2024. For personal use only. No other uses without permission. Copyright ©2024. Elsevier Inc. All rights reserved.

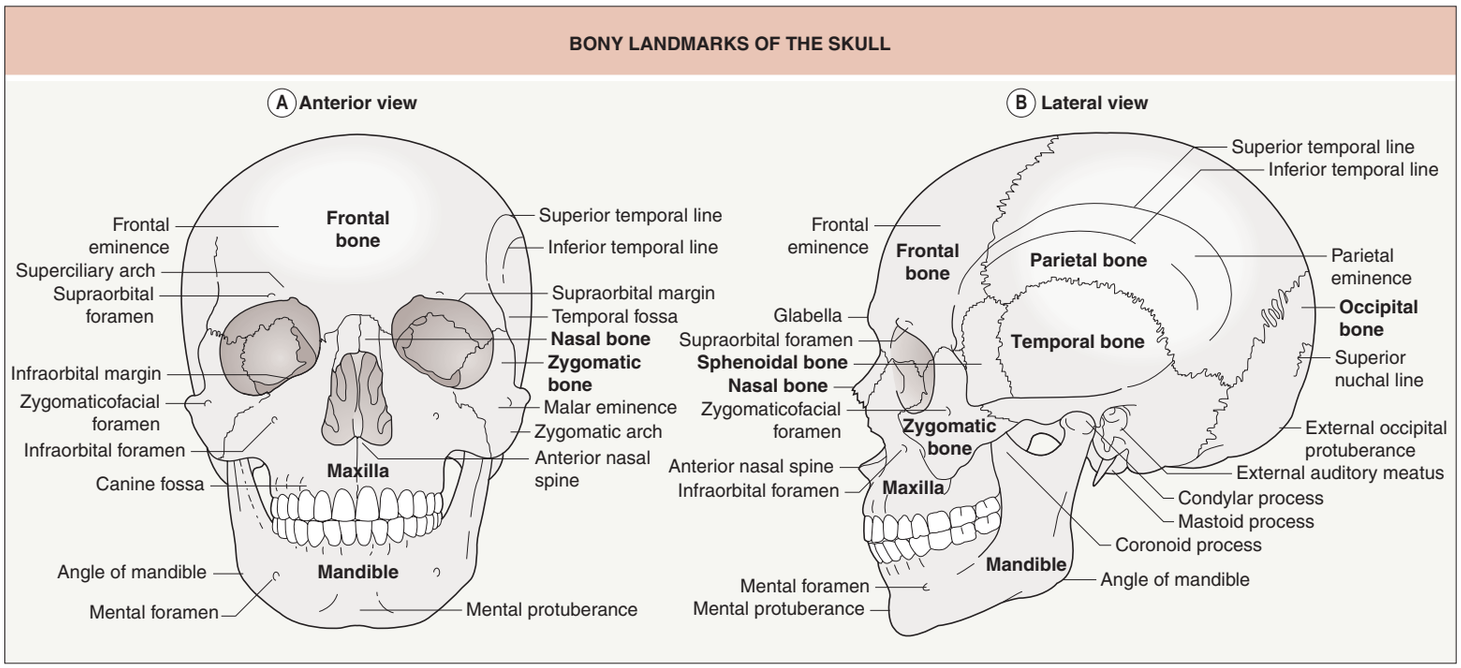

Fig. 142.1 Bony landmarks of the skull. A Anterior view. **B** Lateral view.

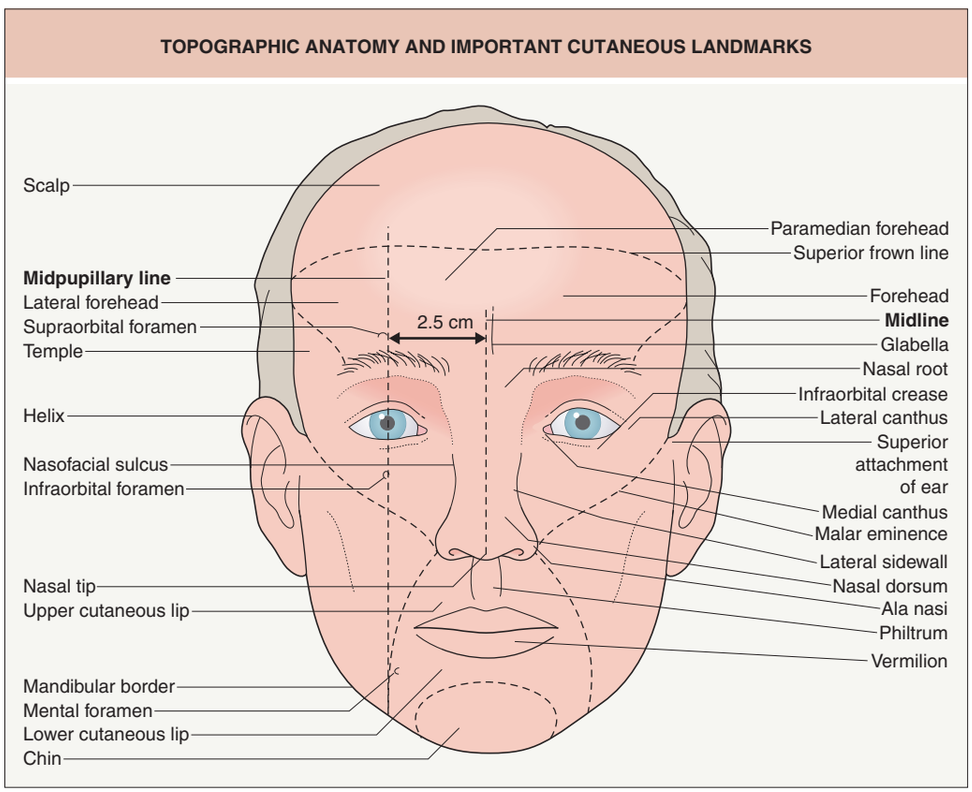

Fig. 142.2 Topographic anatomy and important cutaneous landmarks.

nerve (cranial nerve XI). Cranial nerve XI innervates the trapezius muscle of the back. It may be damaged when operating in the posterior triangle. This may result in chronic shoulder and neck pain, shoulder drop and trapezius atrophy, "winged" scapula, arm paresthesias, and the inability to abduct the arm greater than 80°.

Erb's point designates the area where the cervical plexus emerges from the posterior margin of the sternocleidomastoid muscle (see Figs. 142.4 & 151.6). The spinal accessory nerve also courses through this area on its way to the trapezius muscle (see Fig. 142.4). This surgical danger zone can be visualized by drawing a line connecting the angle of the jaw to the mastoid process. In an adult, a perpendicular line dropped 6 cm from the midpoint of this connector will intersect the posterior border of the sternocleidomastoid where the spinal accessory nerve and cervical plexus emerge[4]. Extreme caution is warranted when dissecting around these anatomic structures, in order to avoid loss of innervation to the trapezius muscle.

SKIN TENSION LINES

Collagen and elastin afford flexibility and extensibility to the skin, and derangements of their architecture or abundance contribute to the aging process. Wrinkles (rhytides) develop over time in predictable areas on

Downloaded for Anonymous User (n/a) at Egyptian Knowledge Bank from ClinicalKey.com by Elsevier on March 10, 2024. For personal use only. No other uses without permission. Copyright ©2024. Elsevier Inc. All rights reserved.

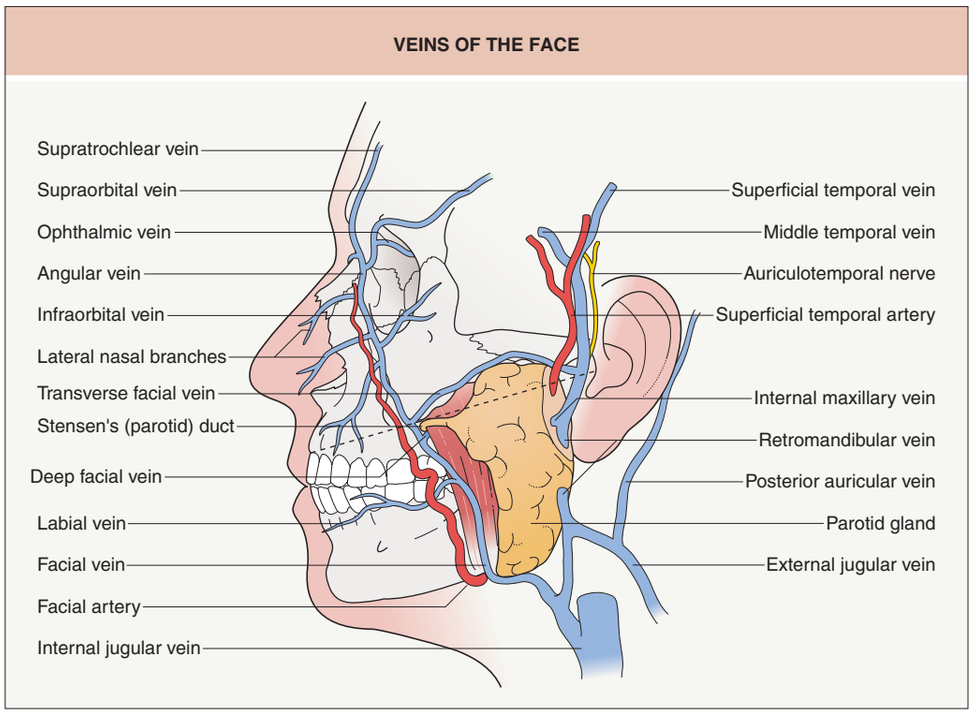

Fig. 142.3 Veins of the face. Stensen's duct can be identified topographically by drawing a line between the tragus and midportion of the cutaneous upper lip (dotted line). It can be palpated as a cord at the middle third of this line.

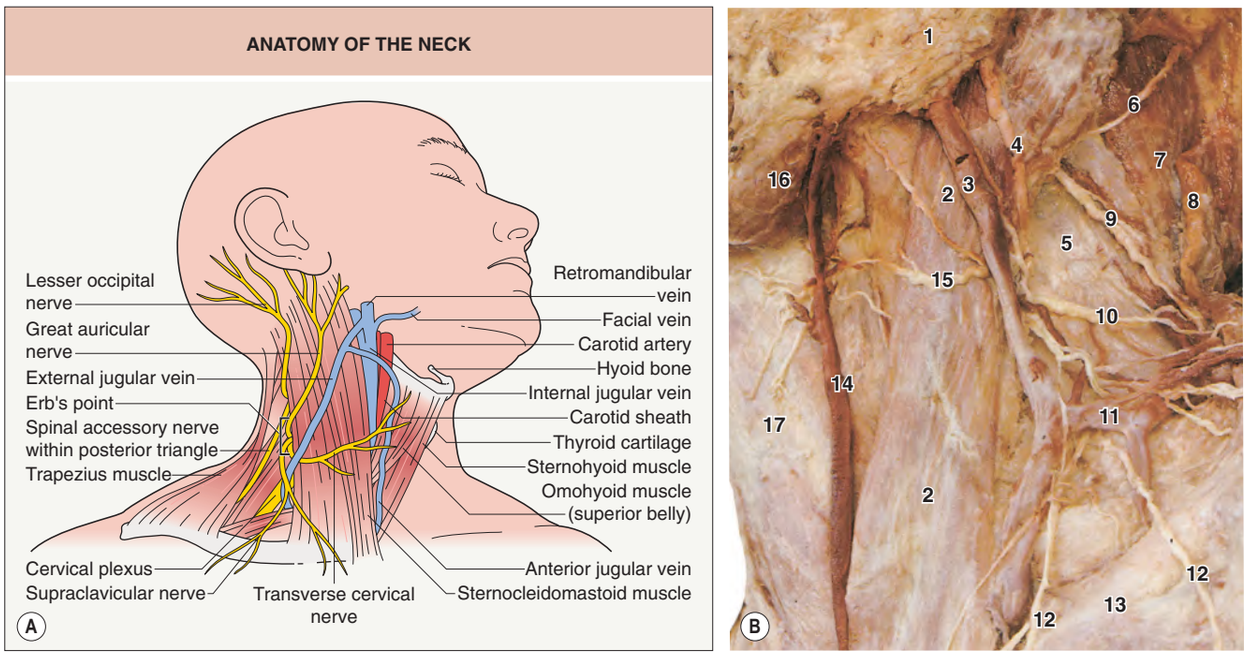

Fig. 142.4 Anatomy of the neck. A The sternocleidomastoid muscle (SCM) divides the neck into anterior and posterior triangles; Erb's point designates the area where the cervical plexus emerges from the posterior margin of the SCM. **B** The platysma was removed completely and the investing layer of deep cervical fascia was removed only from the posterior triangle. The following structures are identified: 1, parotid gland; 2, sternocleidomastoid muscle; 3, external jugular vein; 4, great auricular nerve; 5, prevertebral fascia overlying levator scapulae muscle; 6, lesser occipital nerve; 7, splenius capitis muscle; 8, trapezius muscle; 9, spinal accessory nerve; 10, cervical nerves to the trapezius; 11, superficial cervical vein; 12, supraclavicular nerves; 13, clavicle; 14, anterior jugular vein; 15, transverse cervical nerve; 16, submandibular gland; and 17, investing layer of deep cervical fascia. *B, From Logan B, Reynolds P, Rice S, Hutchings R. McMinn's Color Atlas of Head and Neck Anatomy. 5th ed. Neck superficial dissection II. London: Elsevier; 2017.*

the face. The fine wrinkles seen on an aged face may be referred to as the skin tension lines (Fig. 142.5); on the body, skin tension lines are an important consideration when designing surgical excisions (Fig. 142.6). Many environmental and intrinsic factors, such as ultraviolet exposure, smoking, underlying facial muscles, etc., contribute to the appearance of the expressive human face. A thorough understanding of the derivation and implications of skin tension lines is essential to successful dermatologic surgery.

Continuous tension is exerted on the skin of the head and neck by the muscles of facial expression. A complicated network composed of muscles, elastin, fibrous septae of collagen, and fascial planes contributes to this stress, which eventually results in sagging, wrinkling, and redundant skin. Collagen is flexible but much less extensible than elastic fibers. The resistance to tensile forces by collagen promotes a "youthful" appearance. Over time, the prolonged tension exerted on the skin from many factors forces collagen fibrils to accommodate by way of elongation. Eventually, aged skin manifests the consequences of persistent skin tension. The collagenous tissue becomes increasingly intertwined, diminished in volume, and permanently elongated. This causes the accentuation of skin tension lines[4].

Downloaded for Anonymous User (n/a) at Egyptian Knowledge Bank from ClinicalKey.com by Elsevier on March 10, 2024. For personal use only. No other uses without permission. Copyright ©2024. Elsevier Inc. All rights reserved.

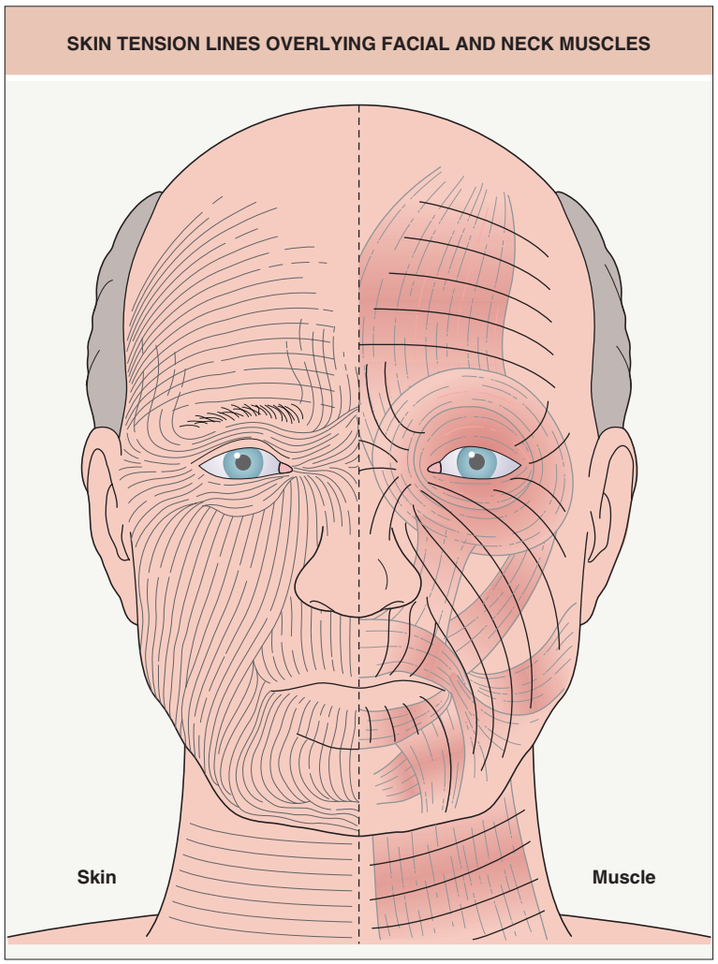

Fig. 142.5 Skin tension lines overlying facial and neck muscles. Note that wrinkles are often directed perpendicularly to the underlying muscle fibers of facial expression.

Elastic fibers promote extensibility (i.e. the ability of skin to stretch) and elasticity (i.e. the skin's capacity to restore its original shape after physical stress). They contribute to the skin tension lines by promoting vector distribution of tension along fascial planes. The elastic properties of the skin explain the phenomenon whereby round surgical wounds relax into an axis parallel to the patient's wrinkles. Tension vectors are increased parallel to the skin tension lines and are diminished perpendicular to them; therefore, the linear appearance of wrinkles is often directed perpendicularly to the underlying muscle fibers of facial expression (see Fig. 142.5). The continuous tension exerted on the overlying skin by these muscles challenges the competency of elastic tissue and collagen. They induce this geometric linearity via fibrous connections to the dermis via the SMAS. For example, the forehead undergoes transverse wrinkling due to contractions of the frontalis muscle, whose fibers run in a cephalocaudad direction. Periocular rhytides are often radially oriented due to underlying contraction of the orbicularis oculi. Similarly, perioral wrinkling occurs under the influence of the concentric orbicularis oris muscle, which induces a radial arrangement of skin tension lines. The procerus muscle causes transverse nasal root lines, and vertical glabellar lines are determined by the corrugator supercilii muscles (Fig. 142.7).

Knowledge of these functional anatomic principles is necessary in surgical and cosmetic dermatology. For example, the successful use of botulinum toxin for the diminution of rhytides requires an understanding of the anatomic relationships between various muscle groups and their influence on the skin tension lines. Proper surgical technique entails placement of incision lines parallel to the skin tension lines in order to achieve excellent cosmesis. It is helpful to determine and even sketch the patient's skin tension lines with a surgical marking pen. This will help orient the axis of incision and guide the closure parallel to, and preferably "buried" within, individual lines of tension.

COSMETIC SUBUNITS

Cosmetic units (i.e. aesthetic, topographic, or regional units) represent the major structural areas of the face that are separated by contour or junctional lines or boundaries (Fig. 142.8). Units are designated based upon their similarity in topographic anatomy, texture and color, solar exposure, hair density, and sebaceous features. The forehead, temples, eyelids, nose, cheeks, upper and lower lips, chin, and ears represent the major cosmetic subunits of the face. Within each division, smaller units are designated that further guide surgical closures. The junctional or contour lines between cosmetic units serve as excellent locations to place incisions and hide surgical scars. They include the hairline, alar and nasolabial creases, eyebrows, the philtrum, the labiomental crease, and the upper and lower vermilion–cutaneous interfaces (see Figs. 142.2 & 142.12).

In general, defects should be repaired with tissue from within the same cosmetic unit in order to preserve topographic consistency and to match skin color and texture. If this cannot be achieved, it is reasonable to utilize tissue from an adjacent aesthetic unit, which will most closely match the skin of the recipient cosmetic unit. The goal is to optimize the match in skin texture, color, actinic damage, and thickness. Scars that cross aesthetic units and boundary lines are obvious and often cosmetically unacceptable. A primary goal of cutaneous surgery is to "respect" the cosmetic subunits.

An appreciation for cosmetic units and contour lines also helps the surgeon determine areas of "recruitable" tissue for closures. Redundant or freely mobile skin can be mobilized from the preauricular folds, neck, nasolabial folds, temple, glabella, the lower and lateral cheeks, and the "jowls"[5]. The potential for such tissue recruitment depends on the patient's age, degree of actinic damage, and skin elasticity. Areas of redundancy or high elasticity may serve as excellent donor sites within or adjacent to the cosmetic subunit which contains a given surgical defect. For example, cheek advancement flaps and temple to lateral forehead advancement and rotation flaps are frequently used for defect repairs.

The forehead unit can be divided into the glabella, temple, and supraeyebrow aesthetic subunits. The transverse creases of this region serve as excellent sites to place cosmetically acceptable incisional scars. The eyelids represent a major cosmetic subunit of the face whose subdivisions correspond to portions of the orbicularis oculi muscles[6] (Fig. 142.9). The inferior pretarsal portion of the upper eyelid is relatively fixed, while the preseptal unit becomes increasingly redundant with age. Over time, progressive laxity of the preseptal unit can cause functional visual impairment in some patients. It is the preseptal unit of the palpebral portion of the lid that is reduced in a blepharoplasty. The infraorbital crease lies between the lower eyelid and the upper cheek.

Nasal cosmetic subunits include the alar groove (which defines the ala nasi) and the columella, which extends from the nasal tip to the junction with the upper cutaneous lip. The root, dorsum, lateral sidewalls, soft triangles, and nasal tip are important landmarks that pose a significant challenge in dermatologic surgery (Fig. 142.10). The nasal tip unit forms the shape of a chevron or heart due to the anatomy of the nasal cartilage (Fig. 142.11). When possible, surgical defects should be contained within the boundaries of a given nasal subunit in order to produce acceptable cosmesis[7].

The philtrum is located above the upper vermilion lip and extends superiorly to the columella of the nose (Fig. 142.12). Because it is a midline structure, even minimal anatomic distortion results in a poor cosmetic outcome. The vermilion lip extends from the vermilion lip–cutaneous junction to the mucous membrane junction. It is a modified epithelium that usually does not contain adnexal structures or salivary glands. Approximation of the vermilion border is crucial to maintaining facial symmetry. The melolabial or nasolabial crease serves as a useful landmark that separates the cheek from the mouth and chin aesthetic units. It is an ideal place to hide suture lines and often serves as a generous donor site for repairs.

The external ear (auricle or pinna) consists of a single cartilaginous plate that results in the complex curves and folds of the ear (Fig. 142.13). The skin is loose on the posterior portion but tightly adherent on the anterior surface.

FREE MARGINS

Free margins of the face are anatomic structures that are in some way discontinuous with adjacent skin. They include the lips, helices, eyelids,

Downloaded for Anonymous User (n/a) at Egyptian Knowledge Bank from ClinicalKey.com by Elsevier on March 10, 2024. For personal use only. No other uses without permission. Copyright ©2024. Elsevier Inc. All rights reserved.

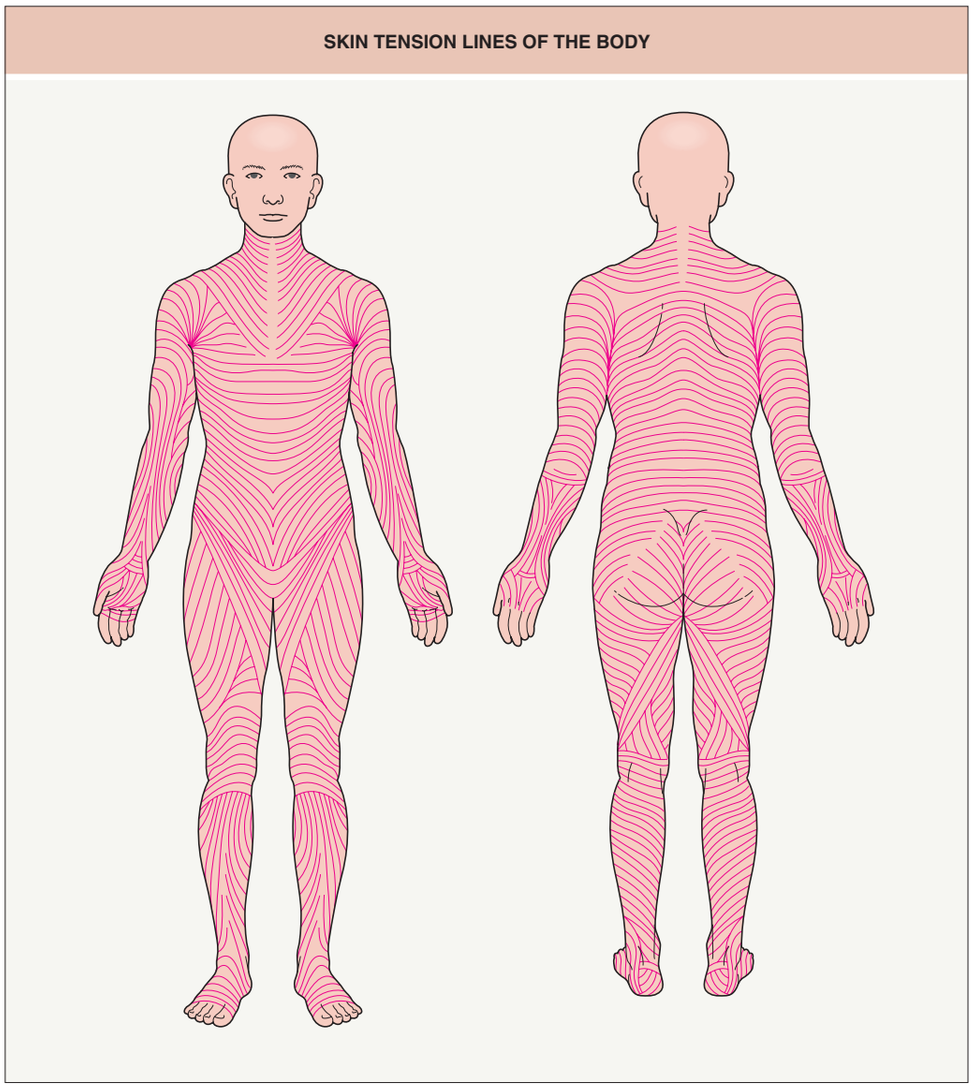

Fig. 142.6 Skin tension lines of the body. See Fig. 142.5 for the skin tension lines of the face and neck.

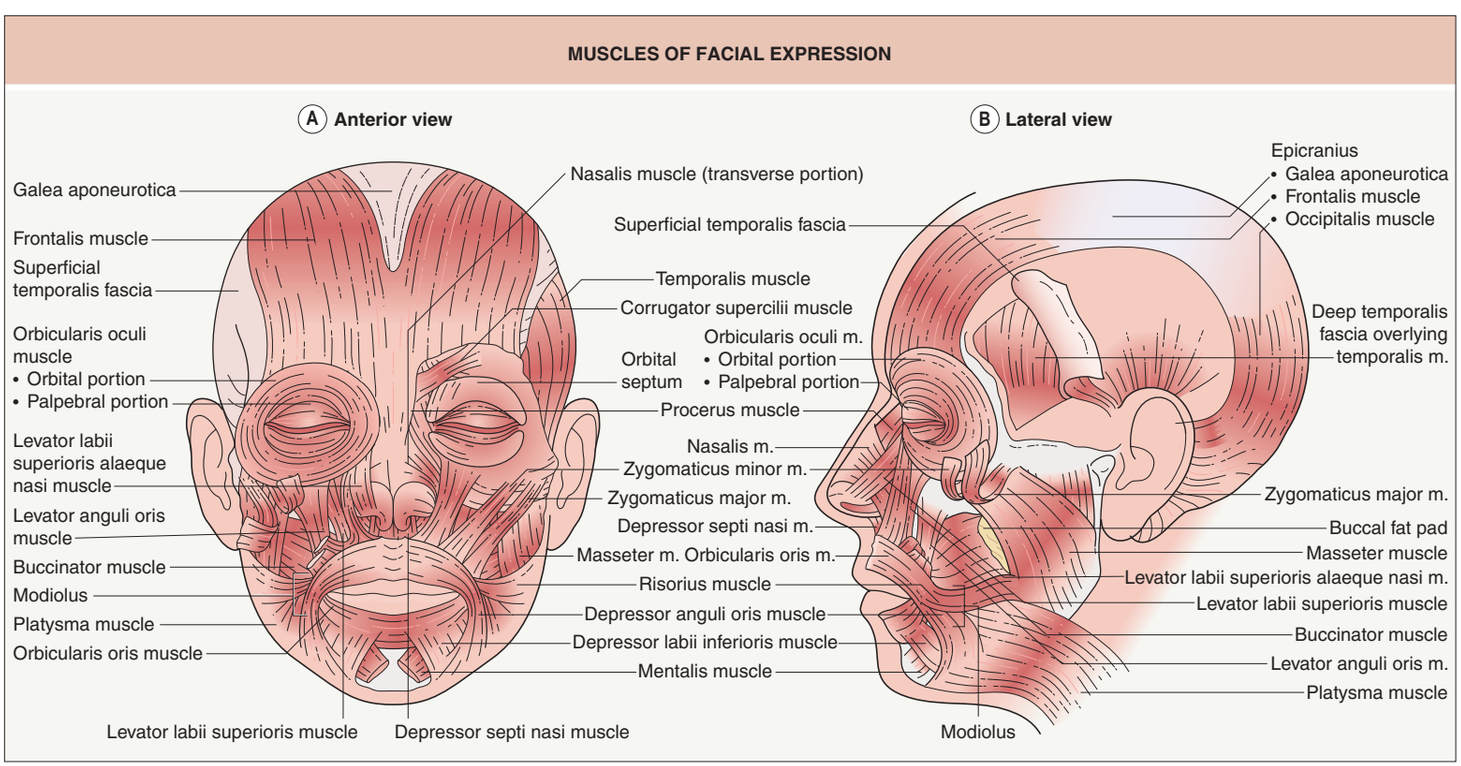

Fig. 142.7 Muscles of facial expression. A Anterior view. **B** Lateral view. The transverse portion of the nasalis muscle is identified. m, muscle.

Downloaded for Anonymous User (n/a) at Egyptian Knowledge Bank from ClinicalKey.com by Elsevier on March 10, 2024. For personal use only. No other uses without permission. Copyright ©2024. Elsevier Inc. All rights reserved.

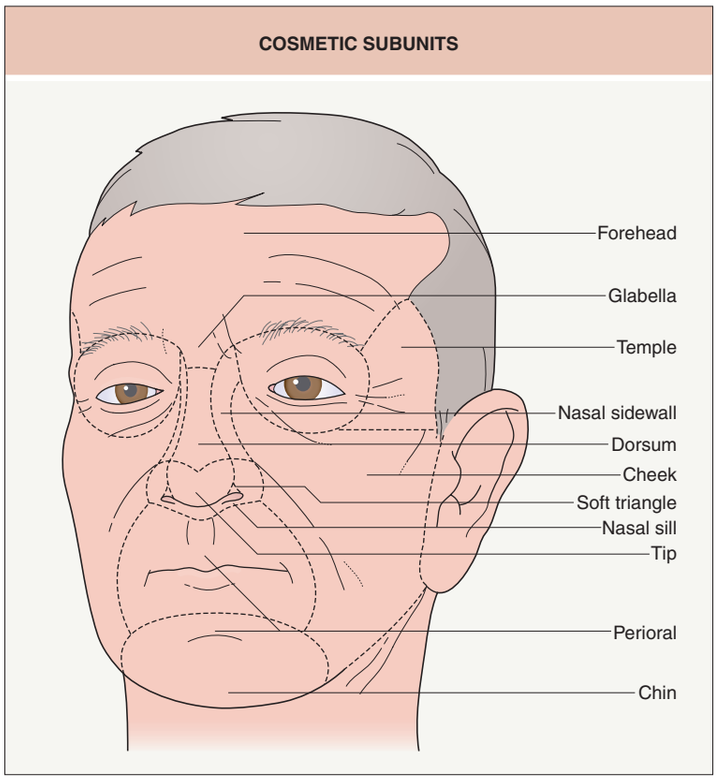

Fig. 142.8 Cosmetic subunits.

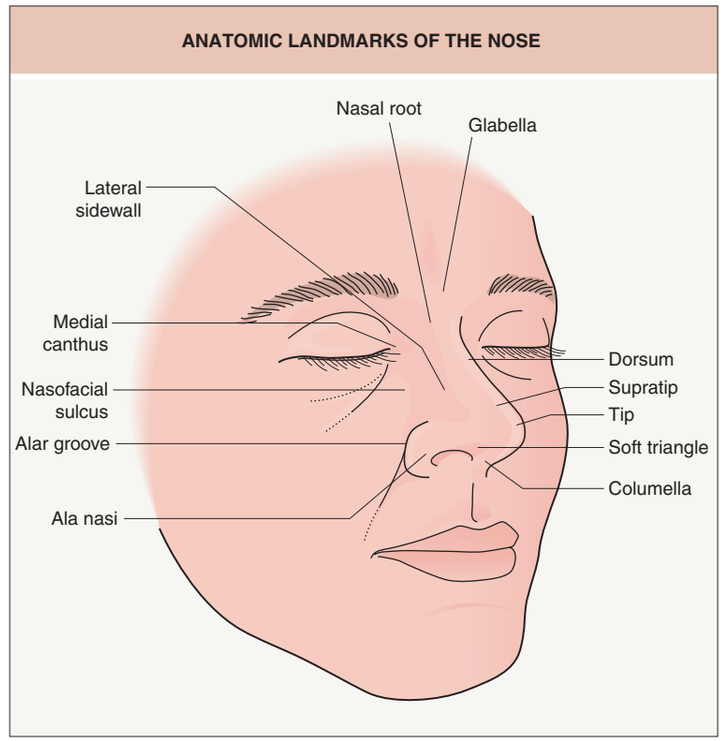

Fig. 142.10 Anatomic landmarks of the nose.

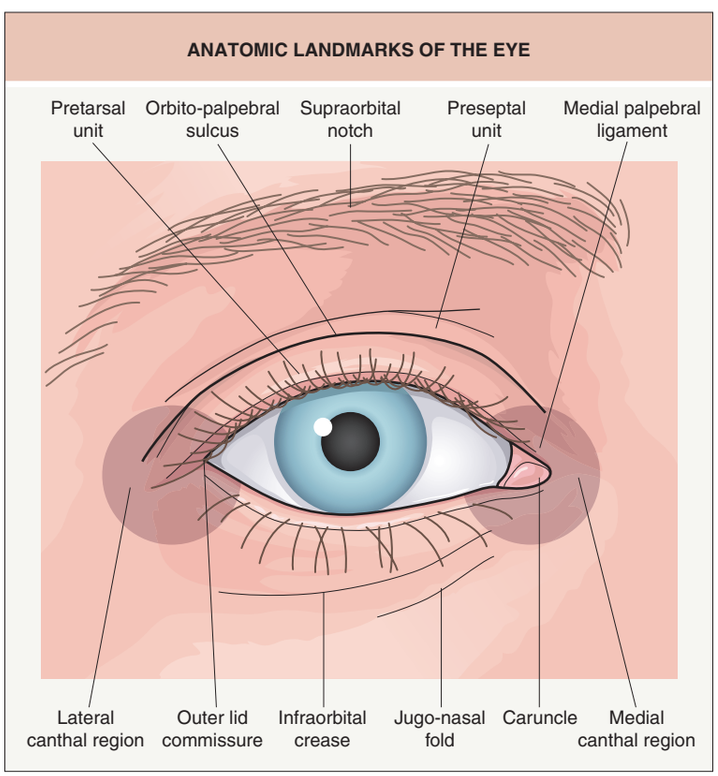

Fig. 142.9 Anatomic landmarks of the right eye.

and nostrils. These areas deserve special attention from the dermatologic surgeon because they do not have evenly distributed tension vectors. This characteristic makes the free margins especially vulnerable to any iatrogenic directional pull. Surgical closures, wound healing, and scar contraction can cause these free margins to lose their cosmetic or functional integrity. Ectropion (eyelid eversion) or eclabium (lip eversion) may ensue. Primary elliptical closures that are parallel to a free margin and second intention healing are not frequently used in these areas.

The opposing force inflicted upon a free margin depends on closure axis orientation, flap or graft design, and the tensile strength and elasticity of the skin. Aged skin is often less able to resist directional vectors. The lower eyelid often becomes especially lax with cumulative actinic damage and age. The "pinch" or "snap" test can be used in free margin evaluation by gently pulling the lower lid away from the eye. Upon release, a competent lower lid should assume its original shape against the globe, while a lax lid will regain its configuration slowly[4]. Instruct the patient to open his or her mouth and gaze upwards while simulating closure options under the eye. This generates the maximum intraoperative tension on the lower eyelid and can help to estimate the risk for distortion of this free margin. No more than 2 mm of inferior pull or "drag" on the lower eyelid can generally be tolerated during cutaneous surgical repairs. Any additional inferior tension puts the patient at high risk for ectropion[8].

Maintenance of cosmesis and function of the lip vermilion is of utmost importance. Elliptical closures often create drag on these free margins, but careful redirection of tension vectors may allow simple closures here. Flaps that can be performed in this area are reviewed in Chapter 147. Although the helical rims are free margins, they are far more "forgiving" than the aforementioned sites. Second intention healing and axial elliptical closures can achieve excellent results on the ear. The tissue is easily dissected and the posterior auricular skin provides excellent mobility. Most patients have some ear asymmetry at baseline, thus making this free margin less cosmetically sensitive.

The nasal tip, alae, and adjacent lateral sidewall require special consideration due to their classification as "free margins" and the underlying cartilage framework that prevents significant tissue mobility. Elevation and distortion of the nasal rim may occur if second intention healing or simple primary closure is attempted (see Fig. 148.9). Full-thickness skin grafts and transposition or rotation flaps from adjacent areas are particularly appealing repairs in this cosmetically sensitive area[9].

THE SUPERFICIAL MUSCULOAPONEUROTIC SYSTEM

The superficial musculoaponeurotic system (SMAS) or superficial fascia of the head and neck region plays an intricate role in coordinating and exaggerating facial expressions. It is a fibromuscular layer that ensheathes and connects the facial muscles. When the regional muscles contract, their impulse is distributed by the SMAS via fibrous

Downloaded for Anonymous User (n/a) at Egyptian Knowledge Bank from ClinicalKey.com by Elsevier on March 10, 2024. For personal use only. No other uses without permission. Copyright ©2024. Elsevier Inc. All rights reserved.

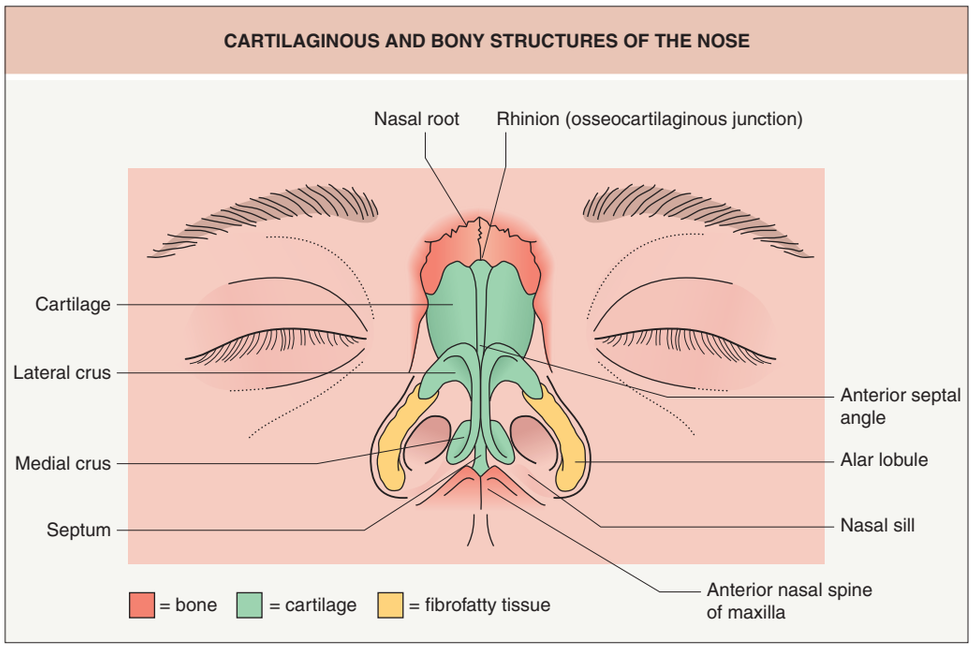

Fig. 142.11 Cartilaginous and bony structures of the nose.

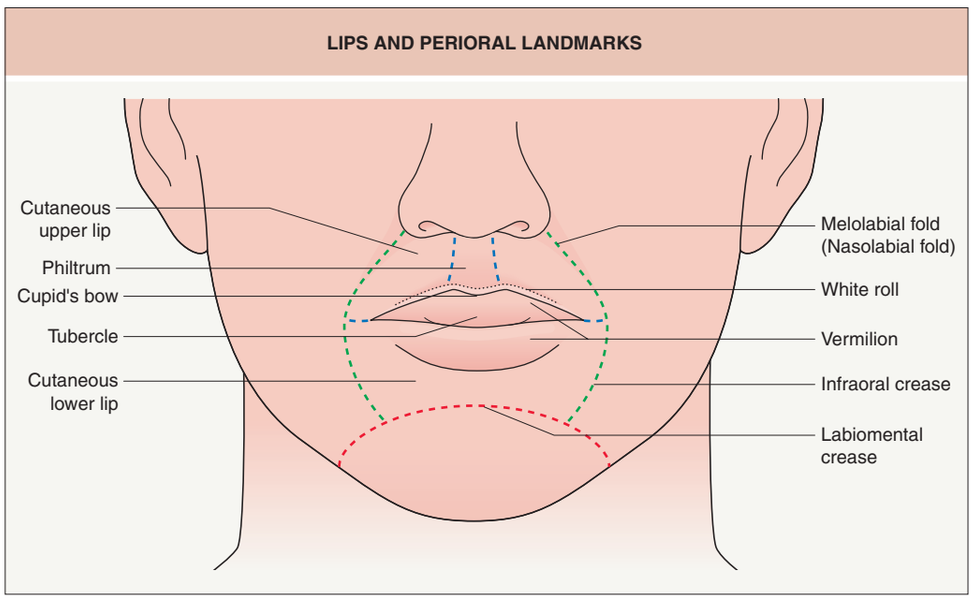

Fig. 142.12 Lips and perioral landmarks.

connections to the skin and other muscle groups. This contributes to organized movements, symmetry in facial expression, and the appearance of skin tension lines. In certain areas where facial musculature is absent, the SMAS layers form a thick, inelastic membrane. These regions are clinically identifiable as the galea aponeurotica of the scalp and the superficial temporalis fascia. Major anatomic structures predictably course in and around the superficial fascia. The dermatologic surgeon can maximize this relatively avascular dissection plane and minimize trauma to important neurovascular structures by using the SMAS as a guide to dissection, tissue mobilization, and closure. Rejuvenation procedures such as facelifts rely on the redistribution and manipulation or plication of the head and neck SMAS.

The deep fascia of the face covers bone, cartilage, muscles of mastication, and visceral structures. It is a continuous sheath, forming periosteum, perichondrium, temporalis muscle fascia, and the parotid–masseteric fascia[1]. This fascia is resistant to stretch and particularly impedes tissue movement on the scalp. Plication or suspension sutures are often used to "tack" overlying structures to the deeper fascia in order to secure tissue and redirect tension vectors.

The SMAS of the cheek is located between the skin and the deeper muscles of mastication. By mobilizing the preauricular SMAS plane, the anterolateral neck and lower cheek below the zygomatic arch can be repositioned as a whole. The SMAS of the cheek is continuous with the orbicularis oculi muscle of the lower eyelid and has several bony attachments in the periocular region[10]. Note that the SMAS of the upper face is discontinuous with the SMAS below the zygoma. This separation is due to different embryologic development patterns of the upper and lower facial muscle groups. The galea aponeurotica of the scalp and the fascia of the superficial temporalis muscle split to envelop the frontalis muscle of the forehead and the occipitalis muscle of the posterior scalp. This superior SMAS terminates 1 cm below the zygomatic arch.

The parotid gland, Stensen's duct, and emerging branches of the facial nerve lie on the deep masseteric fascia. They are covered by thin fibrotic platysma remnants called the parotid fascia, which is covered by the SMAS. The aponeurotic investiture of the central face is thin and often indistinct. The intrinsic nasal muscles and lip elevators and depressors are essentially devoid of superficial fascial interconnections. This makes dissection in this area challenging, because the planes are often difficult to establish and many important anatomic structures are under threat of compromise.

Large sensory nerves and axial blood vessels that supply the face ascend to lie within the SMAS or between the SMAS and subcutaneous fat (Fig. 142.14). Motor nerves run deep to the SMAS and penetrate the muscles of facial expression from their undersurface. Knowledge

Downloaded for Anonymous User (n/a) at Egyptian Knowledge Bank from ClinicalKey.com by Elsevier on March 10, 2024. For personal use only. No other uses without permission. Copyright ©2024. Elsevier Inc. All rights reserved.

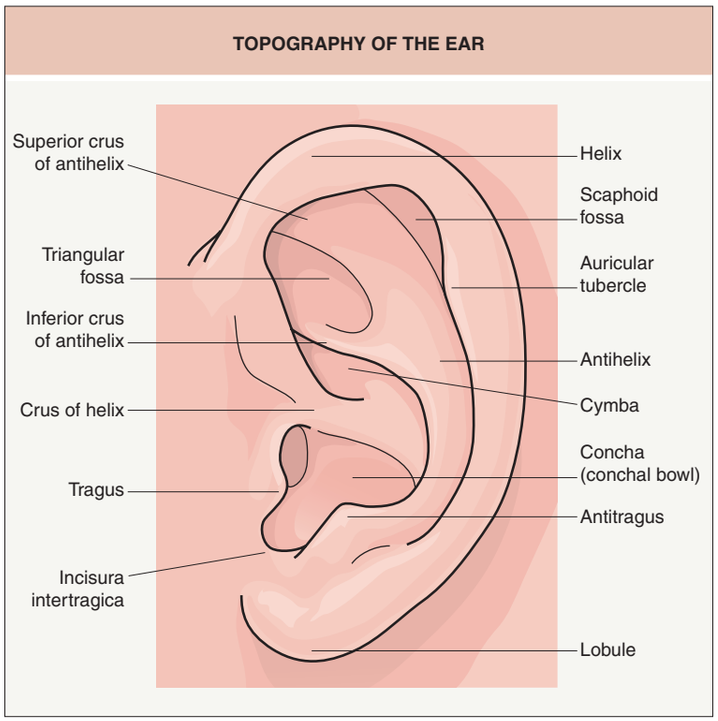

Fig. 142.13 Topography of the ear.

of these anatomic relationships assists the surgeon in establishing a relatively avascular and safe plane of dissection. Blunt dissection of the scalp SMAS separates the galea aponeurotica from the skull periosteum, the superficial temporalis fascia from the deep temporalis fascia, and the subfrontalis SMAS from the forehead periosteum. This is called the subgaleal plane, and it is the ideal avascular dissection plane for scalp surgery. Beware of the supraorbital/supratrochlear neurovascular bundles above the eyebrows when dissecting to the deep galea, as these can be damaged as they exit their respective foramina. In the SMAS–parotid fascial plane of the cheek, the buccal and zygomatic branches of the facial nerve are endangered due to thin protective aponeurotic tissue in this area. The superficial temporal vessels and auriculotemporal nerve course within the superficial temporalis fascia above the zygomatic arch, then assume a superficial plane in the subcutaneous fat.

Surgical undermining and dissection should maximize the horizontal planes provided by the superficial fascial network of the head and neck. Undermining in the subcutaneous fat of the face below the subdermal plexus minimizes the risk to motor nerves, but remember that sensory branches and blood vessels course through this area. There is sparse subcutaneous fat on the dorsal nose, forehead, upper lip, and eyelid. With the exception of the forehead where dissection is usually in the subgaleal plane, the ideal dissection plane in these regions lies just superficial to the thin investing fascia (SMAS) covering the regional muscles of facial expression[11].

In short, the SMAS acts as a unifying infrastructure to the head and neck that creates an anatomic plane for identification and protection of key structures. Knowledge of neurovascular anatomy with respect to the superficial investing fascia will promote effective surgical dissection and closures that minimize functional compromise and maximize cosmesis.

MUSCLES OF FACIAL EXPRESSION

The muscles of facial expression arise from the second branchial arch, are innervated by the facial nerve (cranial nerve VII), and are concentrated in the central facial region. They insert into overlying skin and other local muscle groups and contribute to the relaxed skin tension lines of this region. Fluidity of facial movements is orchestrated by their interaction with the SMAS. A surgeon must have detailed knowledge of these muscles and the potential consequences of disrupting their innervation (Table 142.1).

The epicranius or occipitofrontalis muscle of the scalp has an anterior and posterior region connected by the galea aponeurotica (see Fig. 142.7).

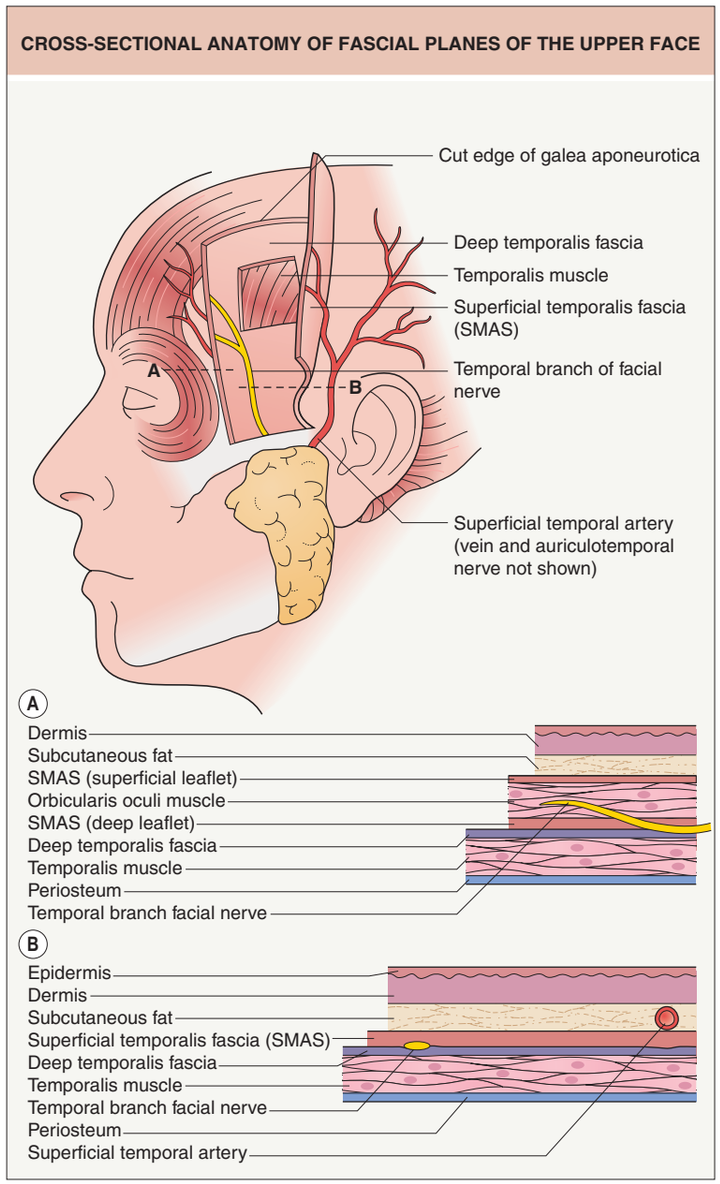

Fig. 142.14 Cross-sectional anatomy of fascial planes of the upper face. SMAS, superficial musculoaponeurotic system.

Contraction of these muscles allows the skin to slide over the scalp. However, humans no longer have voluntary control of the posterior muscle group, which is innervated by the posterior auricular branch of the facial nerve. The *frontalis* muscle, a member of the epicranius complex, begins at the anterior hairline and inserts into the forehead and eyebrow skin. It also connects with the procerus, orbicularis oculi, and corrugator supercilii muscles. Midline vertical forehead skin tension lines occur due to variation in distance between the left and right frontalis bellies. Horizontal skin tension lines occur perpendicular to the frontalis contractile orientation (see Fig. 142.5).

The small *periauricular* muscles, also referred to as the temporoparietalis group, arise from the superficial temporalis fascia and the lateral galea. They help draw back the temporal skin and are innervated by the posterior ramus of the temporal branch of the facial nerve. The *orbicularis oculi* muscle complex is the major group that acts on the eyelid and periorbital skin. It inserts into the medial and lateral canthal tendons and encircles the eye region. Its palpebral portion has a preseptal component overlying the orbital septum and a pretarsal portion overlying the tarsal plate of the eyelid. The orbicularis oculi is intertwined with the procerus, corrugator supercilii, and frontalis muscles and attaches to the superficial temporalis fascia at its lateral border[12].

The *corrugator supercilii* muscle is located over the medial upper orbital rim. It contributes to a "scowling" facial expression by drawing

Downloaded for Anonymous User (n/a) at Egyptian Knowledge Bank from ClinicalKey.com by Elsevier on March 10, 2024. For personal use only. No other uses without permission. Copyright ©2024. Elsevier Inc. All rights reserved.

MUSCLES OF FACIAL EXPRESSION INNERVATED VIA CRANIAL NERVE VII (THE FACIAL NERVE)			
Muscle	**Innervation – facial nerve branch(es)**	**Functions**	**Ipsilateral complications from functional loss**
Frontalis	Temporal	• Raises eyebrows • Aids in opening eyes widely (in conjunction with orbicularis oculi)	• Flattening of horizontal forehead tension lines • Inability to raise lowered/"droopy" eyebrow • May be unable to open eyes widely • Only 15% of patients have cross-innervation*
Corrugator supercilii	Temporal	• Draws brows medially & downward (scowl expression)	• Difficulty scowling/furrowing brow • Rarely occurs due to cross-innervation†
Orbicularis oculi – upper portion	Temporal	• Closes upper eyelids • Voluntary tight closure (orbital component) • Gentle eye closure & blinking (palpebral component) • Aids in tear extraction (palpebral component)	• Difficulty with eye closure • Rarely occurs due to cross-innervation†
Auricular – anterior and superior (also referred to as temporoparietalis)	Temporal	• Draws back temporal skin	
Auricular – posterior	Posterior auricular	• Draws back temporal skin	
Orbicularis oculi – lower portion	Zygomatic	• Closes lower eyelids • Tight and gentle eye closures – similar to upper portion (see above) • Aids in tear extraction	• Difficulty with tight eyelid closure • Lower eyelid droop • Complete loss uncommon due to cross-innervation by temporal branch
Nasalis – alar portion	Zygomatic	• Facilitates alar flaring & compression	
Procerus	Zygomatic	• Causes foreshortening of the nose & "bunny" lines (with nasalis)	
Levator anguli oris	Zygomatic and buccal	• Elevates & retracts mouth angles	• Difficulty smiling • Difficulty with lip seal
Zygomaticus major	Zygomatic and buccal	• Elevates & retracts mouth angles	• Difficulty smiling • Difficulty with lip seal
Buccinator	Buccal	• Pursing of lips • Apposition of cheeks to teeth & gingivae • Prevents cheek overextension during high intraoral pressure	• Inability to whistle • Food accumulates between teeth & buccal mucosa with chewing
Depressor septi nasi	Buccal	• Pulls columella down toward lip	
Nasalis – transverse portion	Buccal	• Facilitates alar flaring & compression	
Zygomaticus minor	Buccal	• Elevates & retracts mouth angles	• May have an effect on smiling expression
Levator labii superioris	Buccal	• Elevates upper lip	
Risorius	Buccal and/or marginal mandibular	• Elevates & retracts mouth angles	• Asymmetric "crooked" smile at rest
Orbicularis oris	Buccal and marginal mandibular	• Pursing & puckering of lips • Apposition of corners of the mouth • Pulls lips against teeth & gingivae	• Difficulty with feeding • Drooling • Muffled speech • Inability to enunciate the letters M, V, F, P, or O
Depressor anguli oris	Marginal mandibular	• Depresses & retracts lip	• Inability to smile‡
Depressor labii inferioris	Marginal mandibular	• Depresses & retracts lip	• Inability to smile‡
Mentalis	Marginal mandibular	• Depresses & retracts lip • Elevates chin • Protrudes lower lip • Dimpling of chin	• Inability to smile‡
Platysma	Marginal mandibular and cervical	• Minor role in retracting mouth angles	

*By the zygomatic branch of the facial nerve.
†By other motor nerves.
‡Normal at rest, but asymmetric expression when smiling.

Table 142.1 Muscles of facial expression innervated via cranial nerve VII (the facial nerve)[4]. Due to a high degree of anastomoses, damage to the zygomatic or buccal branches is often temporary and less debilitating than a similar injury to the temporal branch.

the eyebrows medially and downward. It interdigitates with and is covered by the frontalis and orbicularis oculi muscles. The vertical and oblique skin tension lines of the glabella are caused by contraction of this muscle. The *procerus* muscle overlies the nasal bone and attaches to the nasal root skin. It is responsible for "bunny lines", i.e. skin tension lines exaggerated by wrinkling up the nose. Adjacent to the procerus is the *nasalis* muscle, which courses across the nasal dorsum. Inferiorly, the *depressor septi nasi* muscle, which lies deep to the orbicularis oris, pulls the columella down toward the lip and can form a transverse skin tension line across the philtrum.

An intricate network of interdigitating agonist and antagonist muscle groups contributes to lip movements and oral expression. Lip elevators, depressors, and retractors assist the sphincteric *orbicularis oris* muscle in lip movement. The orbicularis oris muscle is unique in that it has no

Downloaded for Anonymous User (n/a) at Egyptian Knowledge Bank from ClinicalKey.com by Elsevier on March 10, 2024. For personal use only. No other uses without permission. Copyright ©2024. Elsevier Inc. All rights reserved.

bony or cartilaginous attachment. Facial arteries and veins are covered and protected from damage by the lip elevator muscles. The quadratus labii superioris muscle group is comprised of several lip elevators. The *levator anguli oris* and *risorius* muscles are mouth angle retractors and elevators. The *zygomaticus major* muscle travels from the zygoma downward and diagonally to the upper corner of the mouth, where it contributes to the nasolabial fold. *Zygomaticus* major and *minor* muscles are the main contributors to smile formation. The risorius muscle also contributes to a smiling facial expression. The modiolus platform is formed by the convergence of fibers from the orbicularis oris and lip elevators and depressors. It is located 1 cm lateral to the mouth angle and accounts for cheek "dimples" in some patients. It works in synergy with the perioral muscles to facilitate speech enunciation.

The *buccinator* muscle constitutes a large area of the cheek as it courses from the posterior maxillary area to the upper medial surface of the mandible, where it interdigitates with the orbicularis oris. The facial vascular bundle crosses its surface. The parotid duct and transverse facial artery run parallel to each other as the duct pierces the buccinator to enter the mouth at the second maxillary molar. The *depressor anguli oris* (triangularis), *depressor labii inferioris* (quadratus), and the *mentalis* muscles are lip depressors and retractors that antagonize the superior perioral muscle groups. The mentalis muscle has bellies with variable proximities to each other, and a patient with a chin "dimple" or "cleft chin" has a larger distance between mentalis muscle bellies. This is a normal anatomic variant.

The *platysma* muscle runs from the superficial fascia of the chest across the anterior and lateral neck over the mandible to intercalate with the lower lip depressors and retractors. It is continuous with the superficial fascia or SMAS of the lower face. The platysma muscle provides only a thin protective cover to the anterior facial vascular bundle and mandibular branch of the trigeminal nerve.

VASCULAR ANATOMY

The internal carotid artery supplies the eyelids, upper nose and nasal dorsum, forehead, and scalp via sub-branches of its ophthalmic branch. The ophthalmic artery arises behind the eye and branches into the orbital and ocular group. The ocular group supplies the eye itself and its associated muscles. The orbital group includes the supraorbital, supratrochlear, dorsal nasal, and anterior ethmoidal arteries (Fig. 142.15). The supraorbital artery exits the orbit through the supraorbital foramen alongside the supraorbital nerve and perforates the frontalis muscle to ultimately course in the subcutaneous tissue of the forehead and scalp. The supratrochlear artery exits the medial orbit and courses medial to the supraorbital artery to supply the nasal root and the low midline forehead. This artery serves as the axial blood supply for the midline forehead flap often used to repair nasal defects. The success of this flap depends upon isolation and preservation of the supratrochlear artery. The anterior ethmoidal artery exits the nasal passage at the interface of the nasal bone and nasal cartilage to provide arterial supply to the nasal dorsum. The dorsal nasal artery and supratrochlear artery are two of the terminal branches of the ophthalmic artery. The dorsal nasal artery supplies the dorsal nose and crosses the midline over the nasal root to anastomose with the contralateral angular artery. Knowledge of the ophthalmic artery and its branches is of particular importance when planning cosmetic filler injection. Because of their proximal connections, the orbital group of vessels represents a potential site for embolus introduction into the central retinal artery that can lead to complications including blindness (see Fig. 142.15)[13].

While the internal carotid artery contributes to some areas of the scalp and upper face, the external carotid artery supplies most of the face. The facial artery branches off from the external carotid artery and courses deep to the mandible up through or behind the submandibular salivary gland. It passes over the mandible onto the face and can be palpated anterior to the masseter muscle. Its tortuous course maintains a diagonal and superior direction passing alongside the nose and terminating at the medial canthus where it anastomoses with the dorsal nasal artery. The platysma and risorius muscles protect the facial artery near the mandible. As the vessel traverses up the face, it becomes covered by the zygomaticus muscles of the midface and the orbicularis oculi as it nears the medial canthus.

The facial artery gives rise to the inferior and superior labial arteries that course horizontally below and above the lips, respectively. These arteries are found deep to the orbicularis oris in the submucosal plane, but can course more superficially into the submucosa of the lip in elderly patients. After forming the superior labial branch, the facial artery becomes known as the angular artery (Fig. 142.16). At its endpoint near the medial canthal tendon, the angular (or facial) artery anastomoses with the dorsal nasal branch of the ophthalmic artery. Since the ophthalmic artery is a branch of the internal carotid system, this anastomosis joins the internal and external carotid arterial systems. During most of their course, the facial artery and vein are covered by the superficial muscles of facial expression. The facial artery also anastomoses with branches of the internal maxillary (the infraorbital branch)

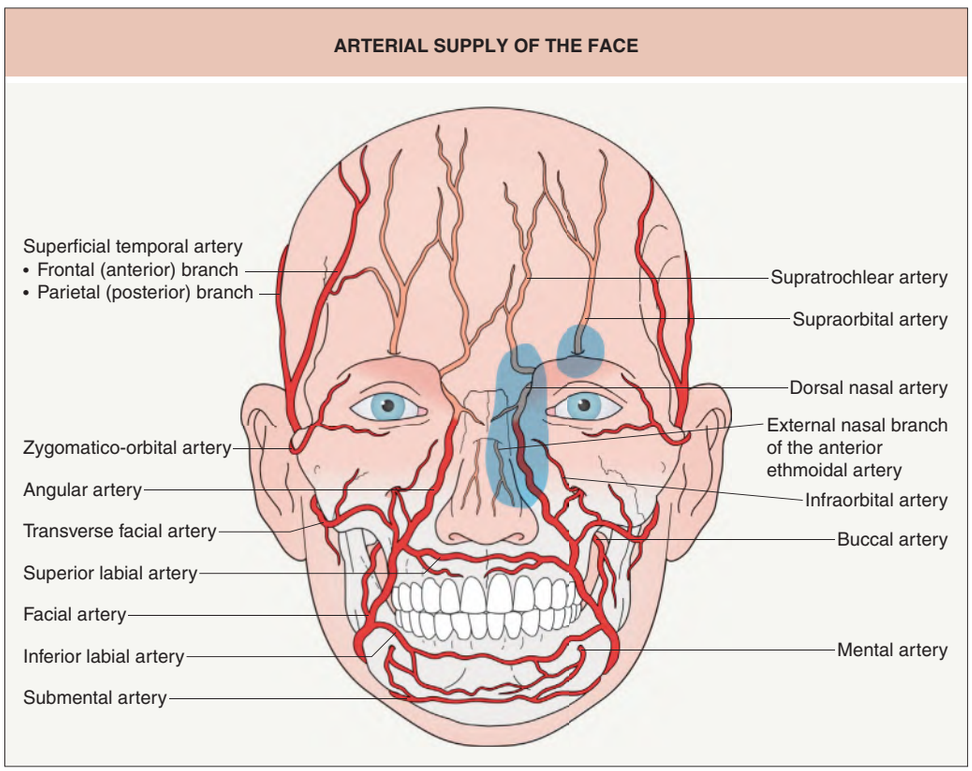

Fig. 142.15 Arterial supply of the face. Light pink designates arteries derived from the internal carotid artery; dark pink, from the external carotid artery. Blue highlighted areas denote high risk for filler injection.

Downloaded for Anonymous User (n/a) at Egyptian Knowledge Bank from ClinicalKey.com by Elsevier on March 10, 2024. For personal use only. No other uses without permission. Copyright ©2024. Elsevier Inc. All rights reserved.

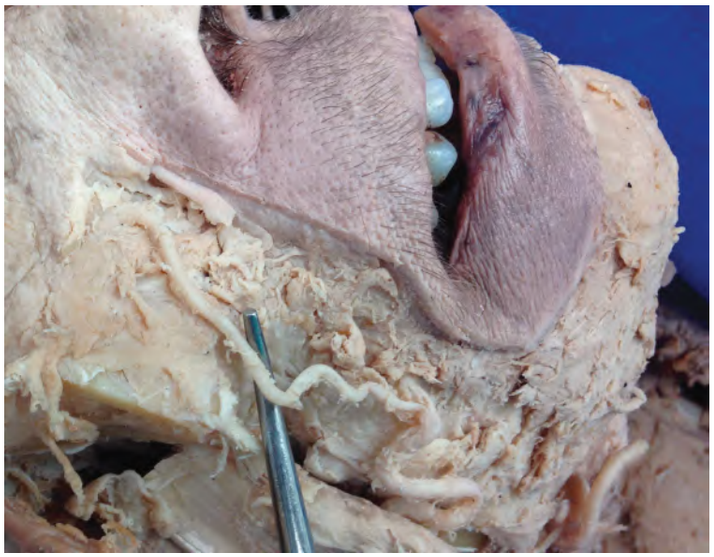

Fig. 142.16 The angular artery. After forming the superior labial branch, the facial artery becomes known as the angular artery.

and superficial temporal (transverse facial) arterial trees. This allows excellent blood supply to the facial skin even if distal arterial branches are cut or tied off during surgery. The high density of arterial supply to the head and neck accounts for its excellent healing potential and viability of local flaps and grafts.

The lateral face, scalp, and forehead are primarily supplied by the superficial temporal artery and its branches. This artery arises in the superficial lobe of the parotid gland as the terminal branch of the external carotid artery. It courses superficially to the main facial nerve trunks, then gives off the transverse facial artery before exiting the parotid gland superficially. The transverse facial artery runs parallel to and 2 cm below the zygomatic arch[4]. The superficial temporal artery exits the parotid and enters the subcutaneous fat in the preauricular crease, where it assumes an ascending vertical course over the zygomatic arch (see Fig. 142.14). It can be easily palpated just medial to the upper tragus of the ear. It runs alongside and superficial to the auriculotemporal nerve within, then above, the SMAS layer of the temple and lateral forehead. The most superficial portion of the superficial temporal artery is often visible in aged patients within the subdermal fat above the galea aponeurotica as it courses cephalad above and anterior to the ear. Here it forms the frontal (anterior) and parietal (posterior) arterial branches that originate just above the uppermost attached portion of the ear (see Fig. 142.15). The forehead, eyebrows, and lateral scalp receive their arterial supply from these branches of the superficial temporal artery. There are many anastomoses on the scalp between the bilateral superficial temporal arteries. Because of this rich supply chain, the entire scalp tissue remains viable even if one of these arteries is occluded. This rich anastomotic network also explains why scalp surgery can be a bloody process. Surgical dissection at the level of the galea aponeurotica may serve to avoid transection of the copious subdermal vascular supply.

Most of the arteries of the face run anterior to and parallel with their corresponding veins (see Fig. 142.3). The veins lack valves and therefore permit two-way flow of venous blood. The facial vein connects to the deep facial vein as it drains the cheek. The deep facial vein parallels the internal maxillary artery and anastomoses with the pterygoid venous plexus medial to the upper mandibular ramus. The facial vein crosses over the submandibular gland, while its corresponding artery passes beneath. It then drains into the internal jugular vein, which connects with the external jugular vein via the retromandibular vein. The facial vein can communicate with the cavernous sinus of the brain via the ophthalmic vein or the pterygoid plexus. The paranasal area and upper lip are the regions drained by this network. This interface may permit skin or wound infections to gain access to the cavernous sinus of the brain from the draining facial or ophthalmic veins, with potentially devastating consequences.

Arterial blood supply to the face is delivered by a rich subdermal plexus that is fed by larger perforating arteries. Wound healing and flap success depend on maximal blood supply to the area. Axial flaps, such as the paramedian forehead flap, incorporate a named subcutaneous artery (e.g. the supratrochlear artery) into their design. Random pattern flaps are maintained by the subdermal arterial plexus and do not rely on a single feeder artery to maintain blood flow. The anastomotic vascular network permits facial arteries to be clamped or tied off during surgery without compromising tissue viability. Nearby ipsilateral or contralateral anastomotic arterial branches can often compensate for any loss in local blood supply.

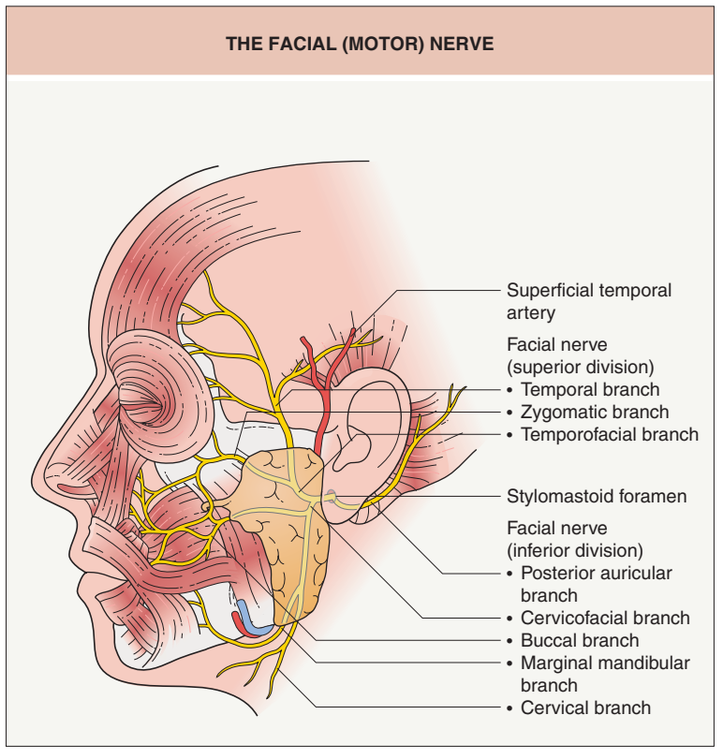

Fig. 142.17 The facial (motor) nerve.

THE FACIAL NERVE

The muscles of facial expression are innervated by the facial nerve, or cranial nerve VII. Upon exiting the skull at the stylomastoid foramen near the level of the earlobe, the facial nerve immediately gives off the posterior auricular branch, which provides motor innervation to the occipitalis and posterior auricular muscles (Fig. 142.17). The remainder of the nerve trunk enters the parotid gland and bifurcates into the lower cervicofacial and the horizontally oriented temporofacial branches. The temporal, zygomatic, buccal, marginal mandibular, and cervical branches arise from these two major rami of the facial nerve. If a line is drawn from the superior border of the tragus to the angle of the mandible, the entrance site of the facial nerve trunk into the parotid gland lies at the midpoint.

After coursing through glandular parotid tissue, branches of the facial nerve travel between the SMAS and the deep fascia before penetrating the lateral underside of the facial muscles. There is significant variability in the course and arborization of this nerve from patient to patient. Cranial nerve VII has two major roots, the smaller of which, via the chorda tympani branch, provides taste sensation to the anterior two-thirds of the tongue; the chorda tympani nerve travels with the lingual nerve (cranial nerve V_3) to the tongue. Sensory innervation to a portion of the external auditory meatus, soft palate, and pharynx is also derived from this small facial nerve root. The submaxillary, submandibular, and lacrimal glands contain parasympathetic fibers of the facial nerve that have secretory effects. In addition to the muscles of facial expression (see Table 142.1), the buccinator, stapedius, posterior belly of the digastric, stylohyoid, and platysma muscles are all innervated by branches of the facial nerve.

While the facial nerve trunk is well protected in adults at its exit from the skull by the mastoid process, tympanic ring, and mandibular

Downloaded for Anonymous User (n/a) at Egyptian Knowledge Bank from ClinicalKey.com by Elsevier on March 10, 2024. For personal use only. No other uses without permission. Copyright ©2024. Elsevier Inc. All rights reserved.

ramus, the surgeon must beware when performing procedures in this anatomic region in children. Because the mastoid process is not fully developed until age five, the main facial nerve trunk lies in a superficial subcutaneous plane behind the earlobe and may be damaged in superficial cutaneous procedures[14]. The major facial nerve branches on the cheek are protected only by a small amount of parotid tissue (superficial lobe), parotid fascia, and subcutaneous fat (Fig. 142.18). If a surgical procedure requires violation of the parotid fascia, meticulous dissection is necessary to avoid major facial nerve damage and subsequent functional disability. Of note, the motor nerves of the face course deeper than the sensory nerves or axial vasculature.

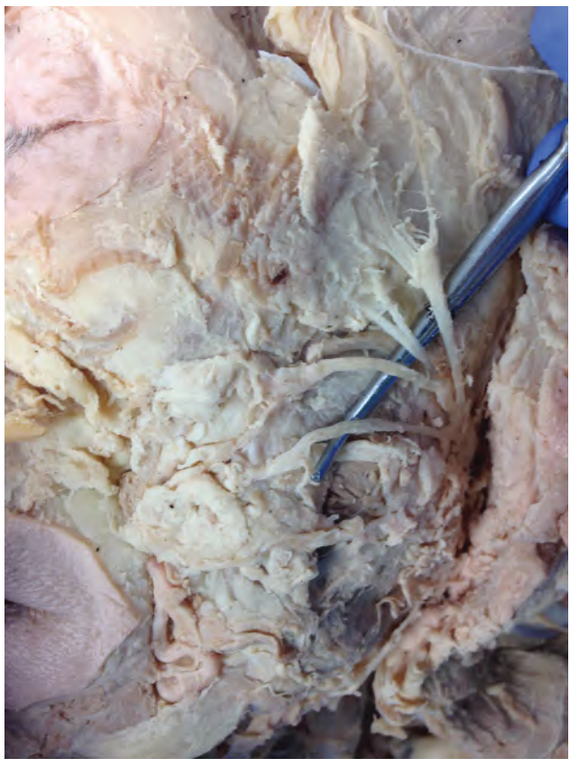

Fig. 142.18 Branches of the facial nerve. Following dissection of the parotid gland, multiple branches are visible; those lifted by the dissecting probe include (from top to bottom): temporal, zygomatic (2 branches), and buccal.

Temporal Branch

The temporal branch of the facial nerve provides motor innervation to the frontalis, upper orbicularis oculi, and corrugator supercilii muscles. It usually has three to five rami that originate over the middle third of the zygomatic arch for a combined approximately 2.5 cm "danger" zone in this area (Table 142.2; see Fig. 151.6). As the most anterior branch of the temporal nerve crosses over the zygomatic arch, it is almost always located, at a minimum, 2 cm posterior to the orbital rim[15]. The most posterior ramus of the temporal branch can be topographically located on the temple 1 cm anterior to a vertical line drawn from the anterior insertion of the ear to the scalp. This posterior ramus runs anterior to the superficial temporal artery and vein. The dermatologic surgeon must exercise caution when working in this area as the superficially located temporal branch is at highest risk for injury within this zone[16].

The temporal branch of the facial nerve courses between the superficial and deep temporalis fascia, penetrating the underside of the frontalis muscle from its lateral edges (see Fig. 142.17). The superficial temporal artery and vein as well as the auriculotemporal sensory nerve run posterior to but more superficially than the temporal nerve branch (see Fig. 142.3). This neurovascular bundle lies in the subcutaneous fat overlying the SMAS of the temple and lateral forehead region. Remember that once the temporal nerve reaches the lateral underbelly of its ipsilateral target muscles, it is most protected. In order to avoid damaging this facial nerve branch, the surgeon should either remain superficial to the SMAS (i.e. the superficial temporalis fascia) or dissect in the subgaleal plane from the medial to lateral forehead. Similar to the other facial nerve divisions, the greatest potential for nerve damage lies in the lateral regions of the face. The central face has many nerve arborizations and protective muscles that usually afford minimal risk for facial motor nerve damage.

Damage to a ramus of the temporal branch of the facial nerve can result in notable cosmetic and functional loss. The temporal branch consists of long, usually singular, and often superficially coursing rami that have few arborizations or cross-innervations. These characteristics make nerve damage and permanent sequelae more likely when cutaneous procedures are performed in the lateral forehead and temporal regions. Even though the upper orbicularis oculi and corrugator supercilii muscles are innervated by the temporal branch, minimal functional or cosmetic compromise occurs, due to cross-innervation by other motor nerves. However, only 15% of patients will have any cross-innervation to the frontalis muscle by the more inferior zygomatic branch of the facial nerve. Such arborization permits retention of some functional mobility of the frontalis should the temporal branch be sacrificed. For the other 85% of patients, violation of the temporal nerve results in motor denervation and the inability to raise a now lowered or "droopy"

SURGICAL DANGER ZONES OF THE HEAD AND NECK				
Danger zone	**Nerve(s)**	**Function**	**Location most susceptible to injury**	**Injury/deficit**
Erb's point	• Spinal accessory • Cervical plexus (lesser occipital, great auricular, transverse cervical, supraclavicular nerves)	• Motor innervation to the trapezius (spinal accessory) • Sensory innervation (cervical plexus)	Draw a line connecting the angle of the mandible to the mastoid process, *then* from the midpoint of this line draw a 6 cm vertical line; the intersection of the lowermost point of the vertical line and the posterior border of the sternocleidomastoid muscle identifies Erb's point	• Inability to elevate the shoulder or abduct the arm >80° • Winged scapula • Loss of sensation to areas of the head/neck
Temple	Temporal branch (facial)	• Motor innervation to the frontalis, orbicularis oculi, corrugator supercilii, and anterior and superior auricular muscles	Draw 2 lines to delineate the zone*: (1) from the inferior earlobe to the lateral edge of the eyebrow; and (2) from the tragus to just above and lateral to the highest forehead crease	• Inability to elevate ipsilateral frontalis muscle • Flattening of forehead tension lines • Brow ptosis
Mandible at the site of the facial artery	Marginal mandibular branch (facial)	• Motor innervation to the orbicularis oris, risorius, and depressors of the lower lip (depressor anguli oris, depressor labii inferioris, and mentalis) muscles	Exits the inferior portion of the parotid gland, then courses over the mandible anterior to the facial artery; it is located 1–2 cm above the inferior border of the mandible	• Inability to smile/ipsilateral crooked smile • Drooling
*In this area, the temporal nerve is protected only by skin, subcutaneous fat, and a thin layer of SMAS.				

Table 142.2 Surgical danger zones of the head and neck. See Fig. 151.6 which also includes the buccal branch of the facial nerve, but the latter is rather deep in the cheek and much less at risk.

Downloaded for Anonymous User (n/a) at Egyptian Knowledge Bank from ClinicalKey.com by Elsevier on March 10, 2024. For personal use only. No other uses without permission. Copyright ©2024. Elsevier Inc. All rights reserved.

eyebrow[4] (see Fig. 151.7). Flattening of the forehead with diminished visibility of wrinkles and skin tension lines on the ipsilateral side is easily noted. The functional loss of the frontalis muscle significantly hampers a patient's ability to communicate non-verbally via facial expression and may have devastating psychosocial consequences. Over time, the inability to raise one's eyebrow can lead to eyebrow and eyelid ptosis and upper visual field compromise as muscular disuse atrophy progresses. Unilateral brow lifts and blepharoplasty may be necessary if the temporal nerve branch is permanently damaged.

Zygomatic and Buccal Branches

The **zygomatic** branch of the facial nerve provides motor innervation to the lower orbicularis oculi, procerus, mouth elevator, and nasal muscles (see Fig. 142.17). Its fibers course horizontally and upwards after emerging from the parotid gland as the second division of the facial nerve (see Fig. 142.18). There is marked variability in the innervation it provides to these muscles; thereby, damage to this nerve branch can have unpredictable outcomes. Generally, injury to the zygomatic branch results in decreased orbicularis oculi function and a diminished ability to close the ipsilateral eyelid tightly. The orbicularis oculi is also innervated in its supraorbital aspect by the temporal branch of the facial nerve. Therefore, complete loss of circumferential periocular motor function is highly unlikely. Other effects may include dysfunction of nasal muscles and lip elevators.

The **buccal** branch is the third division of the facial nerve, and it courses inferiorly to the zygomatic branch in a downward direction on the cheek (see Fig. 142.17). It innervates the orbicularis oris, zygomaticus major and minor, lip elevator, buccinator, and nasal muscles to a variable extent. Damage to this nerve causes buccinator dysfunction that results in accumulation of food between the teeth and the buccal mucosa with chewing, as well as an ipsilateral crooked smile at rest. Approximately 80% of patients have anastomoses between the fibers of the zygomatic and buccal branches[17]. Each branch has two points of arborization, with the first occurring 2 cm anterior to the anterior edge of the parotid gland and the second usually occurring under the modiolus 1 cm lateral to the oral commissure at the anterior aspect of the buccal fat pad. Here the nerves may be damaged due to their superficial anatomy, protected only by the thin fascia of the SMAS, an often underdeveloped risorius muscle, and the subcutaneous fat. At the first branching site near the parotid, the zygomatic and buccal nerves lie between the masseter muscle and the posterior side of the buccal fat pad.

Although damage to the zygomatic or buccal branches of the facial nerve may occur during surgical procedures, subsequent motor dysfunction is often temporary and far less debilitating than a similar injury to the temporal nerve. The high degree of anastomoses between the zygomatic and buccal branches minimizes functional damage and promotes nerve recovery after trauma. Partial paralysis of the perioral muscles may occur, causing variable symptomatic defects in facial expression, including a diminished ability or unilateral defect in forming a smile or pucker, lip pursing, and lip seal formation. Drooling, food accumulation between the cheeks and gingivae, and muffled speech may occur secondary to buccal or zygomatic nerve damage. Orbicularis oculi defects have already been discussed and include lower eyelid droop, which can lead to chronic conjunctivitis, sicca symptoms, and ectropion. Difficulty wrinkling up the nose and inability to flare the nostrils may also occur with zygomatic or buccal branch trauma. Fortunately, most of these symptoms resolve within 6 months due to the extensive ramification and cross-innervation of these branches of the facial nerve.

Marginal Mandibular Branch

The orbicularis oris, mentalis, and lip depressor muscles are innervated by the marginal mandibular branch of the facial nerve. The nerve courses along the angle of the mandible below the parotid gland and continues up over the mandibular body anterior to the facial artery, which can be palpated easily as it courses over the medial mandible (see Fig. 142.17). The marginal mandibular nerve is very susceptible to damage due to its superficial location over the bony edge of the jaw, where it is covered only by fascia and an often unpredictably thin or poorly developed platysma muscle. This facial nerve branch is often composed of only one ramus. The marginal mandibular nerve "communicates" with the buccal branch of the facial nerve in only 10% of patients; therefore, damage to the marginal mandibular nerve can lead to permanent disfiguring and functional defects in facial expression[4]. Normal symmetric facial expression and function of the mouth depends upon the equal and opposite effects exerted by the lip depressors and elevators in conjunction with the orbicularis oris muscle. Characteristically, a patient with marginal mandibular nerve damage cannot form a symmetric smile. There is inability to pull the ipsilateral lower lip downward and laterally or evert the corresponding vermilion border. The end result is a "crooked" smile. The defect is appreciated upon smiling, but is not as apparent when the patient is at rest.

Cervical Branch

The cervical branch of the facial nerve innervates the platysma muscle. This muscle receives nerve fibers from the marginal mandibular nerve as well. Damage incurred to the cervical branch rarely causes functional or cosmetic defects.

SENSORY INNERVATION OF THE HEAD AND NECK

The trigeminal nerve, or cranial nerve V, provides the primary sensory innervation to the face, while the upper cervical nerves (C2, C3) provide sensory supply to the neck, part of the ear, and posterior scalp (Fig. 142.19). The facial, glossopharyngeal, and vagus nerves provide a small portion of sensory innervation to the ear[18]. The trigeminal nerve is the largest cranial nerve. It has motor (to the muscles of mastication), sensory, and parasympathetic functions, supplying secretory fibers (originating from the facial and glossopharyngeal nerves) to the lacrimal and parotid glands. The sensory branches of the trigeminal nerve course more superficially than the trunk of the facial nerve and are therefore readily subject to damage during surgical procedures. Fortunately, most resulting sensory dysfunction is not debilitating or permanent. Transmedian re-innervation after unilateral trigeminal root transection has been demonstrated. This is due to collateral sprouting of sensory nerves from the contralateral trigeminal nerve root[19]. The sensory nerves exist in the superficial plane between the subcutaneous fat and

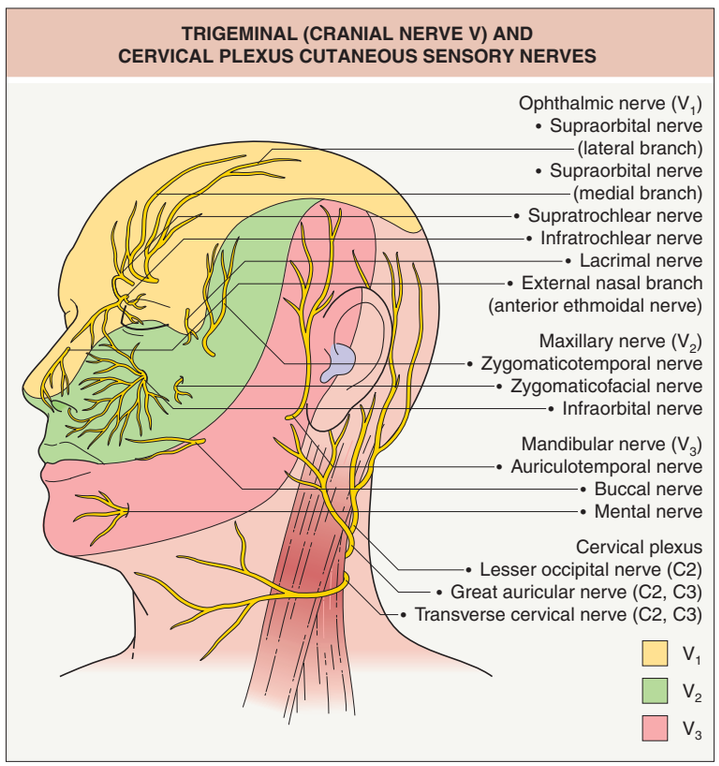

Fig. 142.19 Trigeminal (cranial nerve V) and cervical plexus cutaneous sensory nerves. The concha and external auditory canal are variably innervated by branches of the vagus (cranial nerve X), facial (VII), and auriculotemporal nerves (purple–gray). The upper cervical nerves (C2, C3) also provide sensory innervation to part of the ear as well as to the neck and posterior scalp.

Downloaded for Anonymous User (n/a) at Egyptian Knowledge Bank from ClinicalKey.com by Elsevier on March 10, 2024. For personal use only. No other uses without permission. Copyright ©2024. Elsevier Inc. All rights reserved.

the SMAS and often run together with arteries and veins in neurovascular bundles. Knowledge of the sites where the major branches of sensory nerves emerge from the skull assists the surgeon in performing regional nerve blocks that facilitate facial surgery and improve patient comfort (see Ch. 143).

The trigeminal nerve is divided into three main branches: ophthalmic (V_1), maxillary (V_2), and mandibular (V_3) (see Fig. 142.19). The smallest, uppermost sensory branch is the **ophthalmic** division, which gives off three branches (nasociliary, frontal, and lacrimal nerves) before exiting the orbit. Sensory fibers to the sinuses and upper nasal septal mucosa, as well as secretory parasympathetic fibers to the lacrimal gland (that originate from the facial nerve), are also provided by the ophthalmic branch of the trigeminal nerve. The nasociliary branch gives rise to the infratrochlear nerve and the external branch of the anterior ethmoidal nerve. Sensory innervation to the root of the nose and part of the medial canthus is supplied by the infratrochlear nerve. The nasal dorsum, tip, supratip, and columella derive cutaneous innervation from the external nasal branch of the anterior ethmoidal nerve, which emerges between the upper nasal cartilage and nasal bones. Nerve blocks for the nose rely on knowledge of these anatomic relationships among the sensory nerves. The nasociliary branch also supplies the corneal surface via the ciliary nerve. If an episode of herpes zoster involves the nasal tip, then close ophthalmologic follow-up is warranted due to presumed corneal involvement.

The frontal nerve branch of the ophthalmic division forms the supratrochlear and supraorbital nerves. The exit route (supratrochlear ridge) of the supratrochlear nerve lies 1 cm lateral to the midline on the supraorbital ridge. This branch of the frontal nerve provides sensory innervation to the medial upper eyelid, medial forehead, and frontal scalp. The supraorbital foramen (through which emerges the supraorbital neurovascular bundle) lies 2.5 cm lateral to the midline on the supraorbital ridge (see Fig. 142.2). After penetrating the frontalis muscle to emerge above the frontalis SMAS, the supraorbital nerve provides cutaneous sensation to the forehead, scalp, and upper eyelid. A small lacrimal nerve branch of the ophthalmic division of cranial nerve V innervates the lateral eyelid skin and lies near the upper lateral orbital rim. Frontal nerve blocks, and specifically the supratrochlear and supraorbital block, offer quick and effective anesthesia for surgical procedures of the forehead.

The **maxillary** branch (V_2) of the trigeminal nerve forms the infraorbital, zygomaticofacial, and zygomaticotemporal cutaneous sensory branches (see Fig. 142.19). The infraorbital foramen lies 2.5 cm lateral to midline and 1 cm inferior to the infraorbital rim, in the same vertical line as the supraorbital and mental foramina. The infraorbital neurovascular bundle emerges here to provide significant sensory innervation to the medial cheek, upper lip, nasal sidewall and ala, and the lower eyelid. Infraorbital nerve blocks offer simple and effective anesthesia for much of the cheek, lower eyelid, upper lip, and nose. Lateral to the infraorbital foramen, the zygomaticofacial nerve emerges to innervate the skin of the malar eminence. Cutaneous innervation of the temple and supratemporal scalp region is provided by a third branch of the maxillary division, the zygomaticotemporal nerve. It emerges from the lateral orbital margin at the zygomatic bone. The superior alveolar and palatine nerves are deeper branches of V_2 that provide sensory innervation to the upper teeth, palate, nasal mucosa, and gingiva.

The **mandibular** branch (V_3) is the largest division of the trigeminal nerve and the only one to carry both cutaneous sensory and motor fibers. It supplies cutaneous sensory innervation to the face as well as motor innervation to the muscles of mastication[20]. The auriculotemporal, buccal, and inferior alveolar nerves represent the three main cutaneous branches of V_3. The auriculotemporal nerve emerges from behind the neck of the mandible to course just deep to the superficial temporal artery from the superior margin of the parotid gland in the preauricular sulcus up towards the lateral scalp (see Fig. 142.19). It provides sensory innervation to the external ear and auditory canal, temple, temporoparietal scalp, temporomandibular joint, and tympanic membrane. It also carries parasympathetic secretory fibers to the parotid gland.

The buccal nerve supplies sensory innervation to the cheek, buccal mucosa, and gingiva. It runs deep to the parotid gland over the pterygoid muscle to the upper surface of the buccinator, which it pierces to reach the overlying skin. Because the terminal branches of the buccal nerve are small and numerous, regional buccal nerve block techniques are not feasible anesthetic options. The inferior alveolar branch of V_3 innervates the mandibular teeth as it courses through the mandibular sulcus. Its terminal branch forms the mental nerve, which emerges from the mental foramen in the same topographic line as the supraorbital and infraorbital neurovascular bundles (i.e. 2.5 cm lateral to the midline). The mental vein, artery, and nerve emerge from the mental foramen below the lower second premolar. The lingual nerve supplies sensory innervation to the anterior two-thirds of the tongue, the floor of the mouth, and the lower gingivae. It arises from V_3 and courses parallel and superior to the inferior alveolar nerve.

The cervical plexus is a network of arborizing and anastomosing nerve branches of the ventral rami of the four most superior cervical nerves. It emerges from the mid-posterior margin of the sternocleidomastoid (SCM) muscle at Erb's point to give off three branches, designated as C2, C3, and C4. C2 and C3 compose the great auricular nerve, which runs from the posterior edge of the SCM towards the earlobe in the same plane and path as the external jugular vein (see Figs. 142.4 & 142.19). It innervates the skin of the lateral neck, angle of the jaw, and part of the auricular and postauricular skin.

The lesser occipital nerve (C2) emerges from the same point at the SCM and assumes a course parallel to the SCM upward to innervate the skin of the neck, posterior ear, and postauricular scalp. The transverse cervical nerve (C2 and C3) likewise emerges from behind the SCM and arcs anteriorly around and across the SCM in a transverse direction. Its many terminal branches supply the skin of the anterior neck. The supraclavicular nerve (C3 and C4) emerges from the same point at the SCM posterior margin, then courses inferiorly until it reaches the supraclavicular region, where it terminates, and provides sensory innervation to the anterior chest and shoulder skin (see Fig. 142.4).

Perineural invasion of cutaneous tumors may be encountered by the clinician. Patients are often asymptomatic from dermal nerve twig infiltration by tumor cells, with the diagnosis made only by histopathologic tissue examination. However, some patients may experience sensory abnormalities and, rarely, motor dysfunction. Most of these scenarios occur in the setting of SCC (incidence rates range from 3% to 14%) with <1% of BCCs showing any histologic evidence of perineural spread[17]. Knowledge of the neuroanatomy of the head and neck assists the surgeon in planning adjuvant therapy for patients with nerve involvement.

LYMPHATIC DRAINAGE OF THE HEAD AND NECK

Melanomas, SCCs, Merkel cell carcinomas, and other cutaneous neoplasms may spread via the lymphatics to regional lymph nodes. It is important for the clinician to have a thorough understanding of the lymphatic drainage of the head and neck (Fig. 142.20), as well as the remainder of the body, in order to appropriately stage and manage patients. Before any surgical endeavor is undertaken for a malignancy

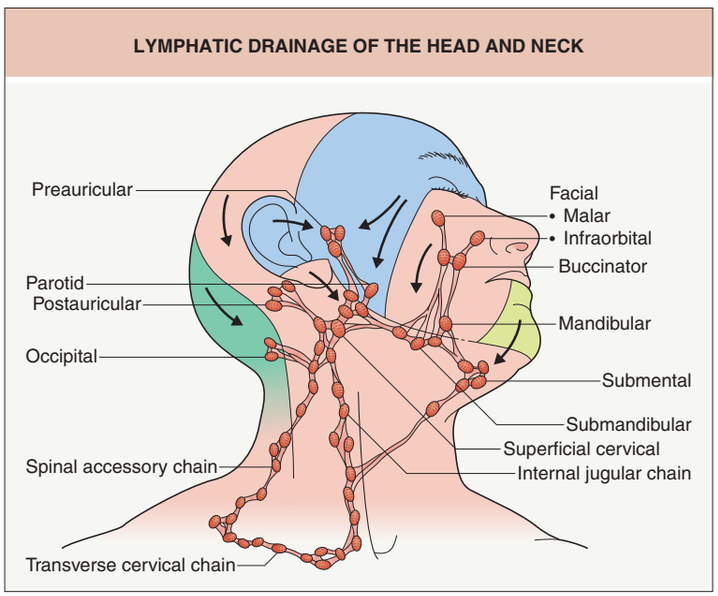

Fig. 142.20 Lymphatic drainage of the head and neck.

Downloaded for Anonymous User (n/a) at Egyptian Knowledge Bank from ClinicalKey.com by Elsevier on March 10, 2024. For personal use only. No other uses without permission. Copyright ©2024. Elsevier Inc. All rights reserved.

with metastatic potential, palpation of regional lymph nodes and basins should be performed. Head and neck cancers usually spread to adjacent lymph nodes in a diagonal direction from cephalad to caudad (see Fig. 142.20). There is a large degree of variability in drainage pathways, but the anatomic location of individual lymph nodes is more consistent from patient to patient. Cutaneous malignancies that breach the papillary dermis may spread from small lymph capillaries to progressively larger and deeper lymphatic trunks in the area. Lymph channels often course along the same directional pathway as the head and neck veins. They are more numerous and often more superficial than the corresponding veins and lie predominantly between the superficial and deep fascial layers.

Important primary lymphatic drainage patterns of the head and neck region include the following: parotid nodes, which often collect from the forehead, temple, and eyelids (upper lateral face); submandibular nodes, from the lower and medial face; and submental nodes, from the central lower lip and chin. Lateral cervical nodes are the common subsequent lymph collection site from these areas.

Parotid nodes may be extraglandular or intraglandular. The extraglandular channels are invested within the parotid sheath. Two-thirds of all individuals will also have one to three pretragal and infra-auricular lymph nodes that are considered part of the parotid node basin[4]. These pre- and infra-auricular nodes drain the ear, the lateral lower cheek, the frontolateral scalp, and the forehead, as well as the nasal root. Drainage of the parotid unit may then follow the external or internal jugular vein in the jugular lymph node chain; therefore, palpation for nodes from the site of the cutaneous lesion to the supraclavicular and even axillary nodal basins is recommended.

Submandibular nodes should be examined as the patient relaxes the neck muscles and tilts the chin down. This nodal group drains the gingival and mucous membranes, lower eyelids, anterior two-thirds of the tongue, lips, nose, and medial cheeks. The submental nodes (up to eight) of the neck lie beneath the platysma and drain the anterior third of the tongue and floor of the mouth, in addition to the lower middle lip, chin, and medial lower cheeks. They are best examined by elevating the chin and asking the patient to engage the platysma. Submental nodes frequently drain bilaterally or contralaterally and empty into the submandibular basin or directly into the internal jugular lymphatic chain. Note that up to one-quarter of healthy individuals have small (less than 1 cm), non-fixed, palpable submental nodes[4].

The superficial lateral cervical nodes are adjacent to the infra-auricular parotid nodes and lie near the high external jugular vein. Use the sternocleidomastoid muscle as a landmark to palpate these nodes (up to four) over its cephalad portion. Deeper lateral cervical nodes include the spinal accessory, internal jugular, and transverse cervical chains, which form a triangle on the neck. The internal jugular chain is the main lymphatic collection trunk of the head and neck and may contain up to 25 lymph nodes in each patient. The internal jugular chain on the right often drains into the subclavian vein, whereas the left-sided lymphatic chain empties into the thoracic duct. These nodes can be palpated by rolling two fingers over the area of the carotid triangle.

Acute or chronic lymphedema may ensue after transection of larger lymphatic channels or nodes, or even after disruption of smaller channels in areas (e.g. infraorbital) with limited or vulnerable lymphatic drainage. Adequate drainage can be achieved by orienting flaps in the same direction as lymphatic patterns. The surgeon must be mindful of the variability in drainage patterns and sites and the fact that malignancies do not respect the midline. Since cross-communication between lymphatics may result in contralateral drainage, bilateral examination for lymphadenopathy should be undertaken before a neoplasm is excised.

Additional figures and table, Sensory innervation of the head and neck, available in our eBook (see inside front cover for access code).

REFERENCES

1. Dzubow LM. Tissue movement – a macrobiomechanical approach. *J Dermatol Surg Oncol*. 1989;15:389–399.
2. Dzubow LM. *Facial Flaps: Biomechanics and Regional Application*. Norwalk: Appleton & Lange; 1990.
3. Robinson JK, Sengelmann RD, Hanke CW, Siegel DM. *Surgery of the Skin: Procedural Dermatology*. St Louis: Mosby; 2005.
4. Salasche SJ, Bernstein G, Senkarik M. *Surgical Anatomy of the Skin*. Norwalk: Appleton & Lange; 1988.
5. Summers BK, Siegle RJ. Facial cutaneous reconstructive surgery: general aesthetic principles. *J Am Acad Dermatol*. 1993;29:669–681.
6. Zide BM, Jelks GW. *Surgical Anatomy of the Orbit*. New York: Raven Press; 1985.
7. Stegman SJ, Tromovitch TA, Glogau RG. *Cosmetic Dermatologic Surgery*. 2nd ed. St Louis: Mosby; 1990.
8. Larrabee WF, Makielski KH. *Surgical Anatomy of the Face*. New York: Raven Press; 1993.
9. Tromovitch TA, Stegman SJ, Glogau RG. *Flaps and Grafts in Dermatologic Surgery*. Chicago: Year Book; 1989.
10. Gosain AK, Yousif NJ, Madiedo G, et al. Surgical anatomy of the SMAS: a reinvestigation. *Plast Reconstr Surg*. 1993;92:1254–1265.
11. Burger GC, Menick FJ. *Aesthetic Reconstruction of the Nose*. St Louis: Mosby; 1994.
12. Harvey DT, Taylor SR, Itani KM, Loewinger RJ. Mohs micrographic surgery of the eyelid: an overview of anatomy, pathophysiology, and reconstruction options. *Dermatol Surg*. 2013;39:673–697.
13. Carruthers JD, Fagien S, Rohrich RJ, et al. Blindness caused by cosmetic filler injection: a review of cause and therapy. *Plast Reconstr Surg*. 2014;134:1197–1201.
14. Myckatyn TM, Mackinnon SE. A review of facial nerve anatomy. *Semin Plast Surg*. 2004;18:5–11.
15. Prendergast PM. Anatomy of the face and neck. In: Shiffman MA, Di Giuseppe A, eds. *Cosmetic Surgery*. Berlin: Springer; 2013:29–46.
16. Brown SM, Oliphant T, Langtry J. Motor nerves of the head and neck that are susceptible to damage during dermatological surgery. *Clin Exp Dermatol*. 2014;39:677–682.
17. Carlson KC, Roenigk RK. Know your anatomy: perineural involvement of basal and squamous cell carcinoma on the face. *J Dermatol Surg Oncol*. 1990;16:827–833.
18. Drake RL. *Gray's Atlas of Anatomy*. Churchill Livingstone; 2007.
19. Robinson PP. Recession of sensory loss from the midline following trigeminal sensory root section: collateral sprouting from the normal side? *Brain Res*. 1983;259:177–180.
20. Leach BC, Kulbersh JS, Day TA, Cook J. Cranial neuropathy as a presenting sign of recurrent aggressive skin cancer. *Dermatol Surg*. 2008;34:483–497.

Downloaded for Anonymous User (n/a) at Egyptian Knowledge Bank from ClinicalKey.com by Elsevier on March 10, 2024. For personal use only. No other uses without permission. Copyright ©2024. Elsevier Inc. All rights reserved.

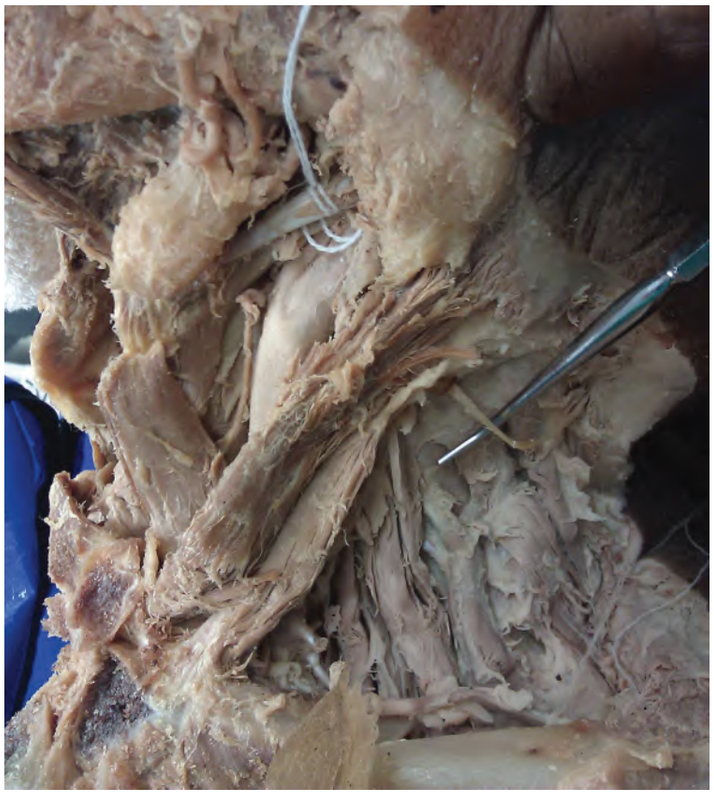

eFig. 142.1 Location of the spinal accessory nerve (cranial nerve XI) within the posterior triangle of the neck. The spinal accessory nerve (lifted by the dissecting probe) traverses behind the sternocleidomastoid muscle towards the trapezius muscle.

Downloaded for Anonymous User (n/a) at Egyptian Knowledge Bank from ClinicalKey.com by Elsevier on March 10, 2024. For personal use only. No other uses without permission. Copyright ©2024. Elsevier Inc. All rights reserved.

eFig. 142.2 Facial artery and other anatomic structures of the lower face and neck. The facial artery (6) is seen passing behind the submandibular gland and then over the mandible in a location anterior to the masseter. The following structures are identified: 1, masseter muscle; 2, marginal mandibular branch of facial nerve; 3, parotid gland; 4, cervical branch of facial nerve; 5, jugulodigastric lymph nodes; 6, facial artery; 7, hypoglossal nerve; 8, facial vein; 9, posterior branch of retromandibular vein; 10, sternocleidomastoid muscle (SCM); 11, great auricular nerve; 12, external jugular vein; 13, transverse cervical nerve; 14, spinal accessory nerve; 15, clavicular head of SCM; 16, sternal head of SCM; 17, common carotid artery; 18, internal carotid artery; 19, external carotid artery; 20, submandibular gland; 21, body of mandible; and 22, buccal fat pad. *From Logan B, Reynolds P, Rice S, Hutchings R: McMinn's Color Atlas of Head and Neck Anatomy. 5th ed. Neck superficial dissection III. London: Elsevier; 2017.*

Downloaded for Anonymous User (n/a) at Egyptian Knowledge Bank from ClinicalKey.com by Elsevier on March 10, 2024. For personal use only. No other uses without permission. Copyright ©2024. Elsevier Inc. All rights reserved.

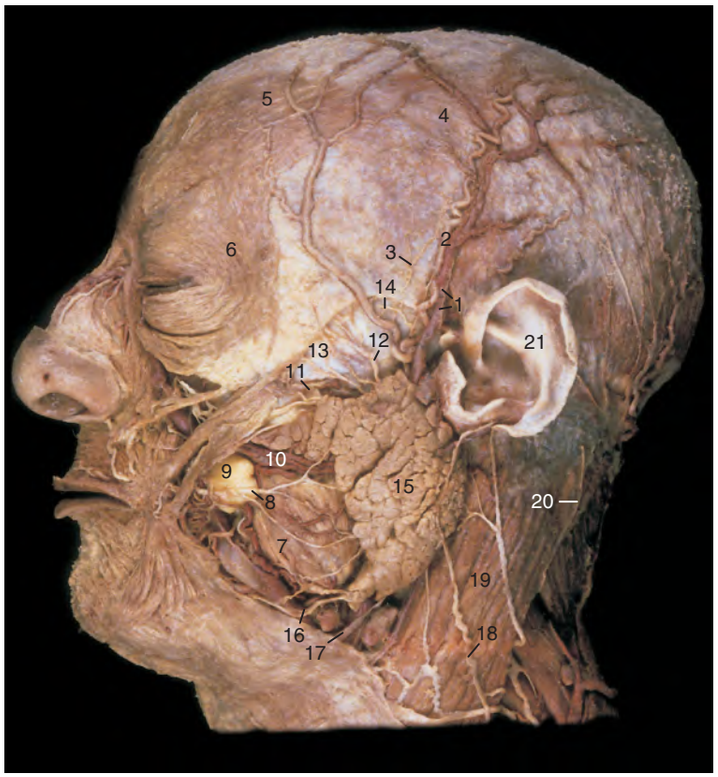

eFig. 142.3 Branches of the facial nerve. The following structures are identified: 1, auriculotemporal nerve; 2, superficial temporal artery; 3, zygomaticotemporal nerve; 4, galea aponeurotica; 5, frontalis muscle; 6, orbicularis oculi muscle; 7, masseter muscle; 8, buccal branches of facial nerve; 9, buccal fat pad; 10, parotid duct; 11, transverse facial artery; 12, zygomatic branch of facial nerve; 13, zygomatic arch; 14, temporal branch of facial nerve; 15, parotid gland; 16, marginal mandibular branch of facial nerve; 17, cervical branch of facial nerve; 18, great auricular nerve; 19, sternocleidomastoid muscle; 20, lesser occipital nerve; and 21, cartilage of pinna. *From Logan B, Reynolds P, Rice S, Hutchings R: McMinn's Color Atlas of Head and Neck Anatomy. 5th ed. Face superficial dissection B. London: Elsevier; 2017.*

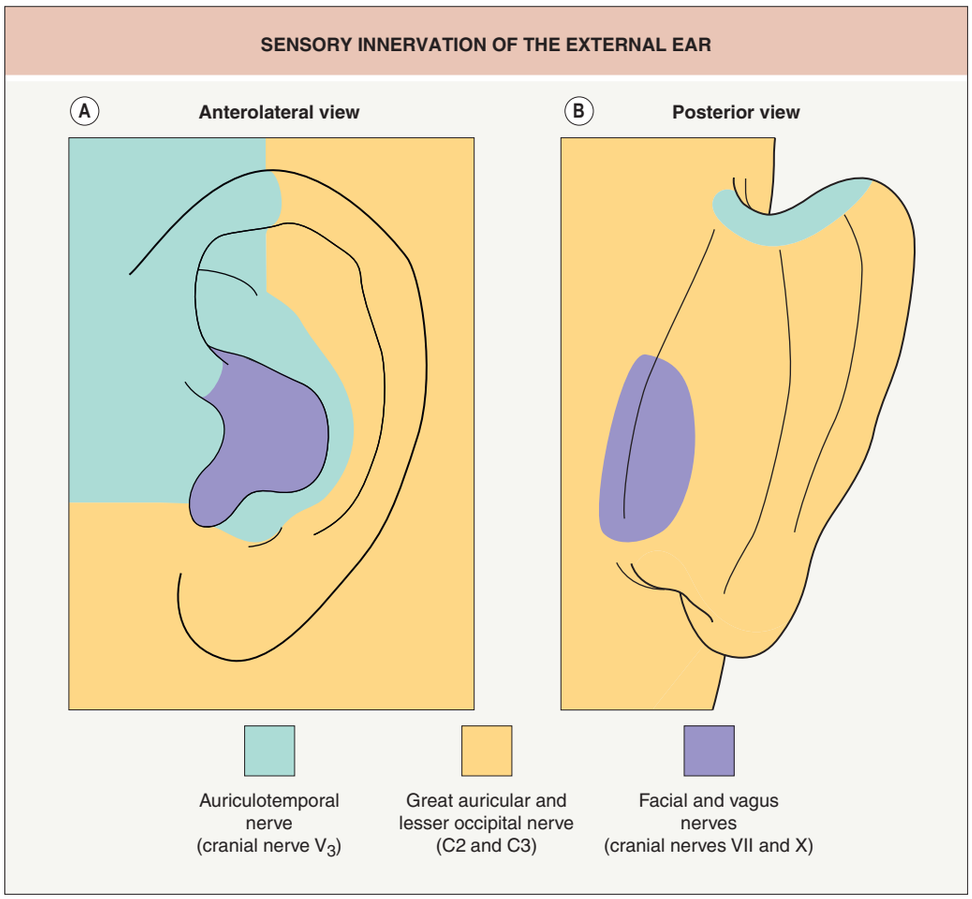

eFig. 142.4 Sensory innervation of the external ear. **A** Anterolateral view. **B** Posterior view.

Downloaded for Anonymous User (n/a) at Egyptian Knowledge Bank from ClinicalKey.com by Elsevier on March 10, 2024. For personal use only. No other uses without permission. Copyright ©2024. Elsevier Inc. All rights reserved.

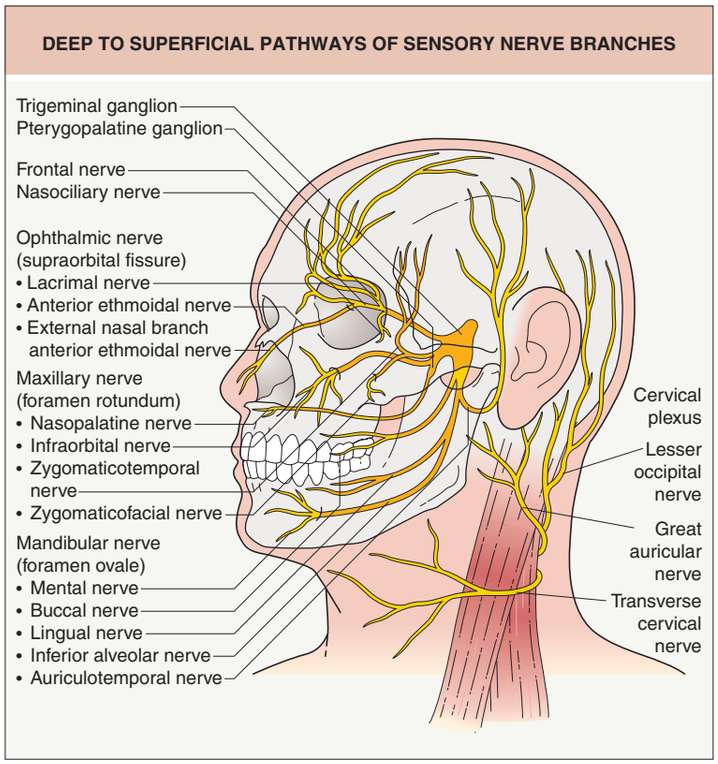

eFig. 142.5 Deep to superficial pathways of sensory nerve branches.

SENSORY INNERVATION OF THE HEAD AND NECK

- **Trigeminal nerve**
  - Ophthalmic branch (V_1)
    - Nasociliary – anterior nasal septum, nasal wall, cornea, iris, ethmoid/sphenoid sinuses
    - Infratrochlear – root of nose, medial canthus
    - Anterior ethmoidal (external nasal branch) – nasal dorsum, tip, supratip, columella
    - Ciliary – corneal surface
    - Frontal
      - Supratrochlear – medial upper eyelid, medial forehead, frontal scalp
      - Supraorbital – forehead, scalp, upper eyelid
    - Lacrimal – lateral eyelid
  - Maxillary branch (V_2)
    - Infraorbital – medial cheek, upper lip, nasal sidewall and ala, lower eyelid
    - Zygomaticofacial – malar eminence
    - Zygomaticotemporal – temple, supratemporal scalp
    - Superior alveolar and palatine – upper teeth, palate, nasal mucosa, gingiva
  - Mandibular branch (V_3)
    - Auriculotemporal – external anterior ear and external auditory canal, temple, temporoparietal scalp, temporomandibular joint, tympanic membrane
    - Buccal – cheek, buccal mucosa, gingiva
    - Inferior alveolar – mandibular teeth; chin and lower lip (mental nerve)
    - Lingual – anterior two-thirds of tongue, floor of mouth, lower gingivae
- **Vagus nerve** (X) – external auditory canal, concha, postauricular sulcus
- **Facial nerve** (VII) – external auditory canal, postauricular sulcus
- **Great auricular nerve** (C2, C3) – lateral neck, angle of the jaw, posterior and inferior ear, portions of the helical rim, postauricular scalp
- **Facial nerve (VII)** – external auditory canal, concha, postauricular sulcus
- **Vagus nerves** – external auditory canal, concha, postauricular sulcus
- **Lesser occipital nerve** (C2) – neck, postauricular scalp
- **Transverse cervical nerve** (C2, C3) – anterior neck
- **Supraclavicular nerve** (C3, C4) – anterior chest, shoulder

eTable 142.1 Sensory innervation of the head and neck.

Downloaded for Anonymous User (n/a) at Egyptian Knowledge Bank from ClinicalKey.com by Elsevier on March 10, 2024. For personal use only. No other uses without permission. Copyright ©2024. Elsevier Inc. All rights reserved.